Problèmes posés à l ’adolescence et chez l ’adulte atteint de cardiopathie congénitale non guérie

L Iserin
Paris

de nouvelles situations

- nouvelle médecine : passage pédiatrie à l'age adulte pour le médecin et le malade
- prévention de l'endocardite
- contraception
- grossesse
- emploi
- assurance
- qualité de vie

de nouveaux problèmes

- spécialité particulière : complexité, diversité
- succès de la chirurgie passée (tétralogie de Fallot)
- présent (Transposition de gros vaisseaux)
- avenir : progrès techniques des deux spécialités (imagerie non invasive,cathéterisme , rythmologie interventionnelle)

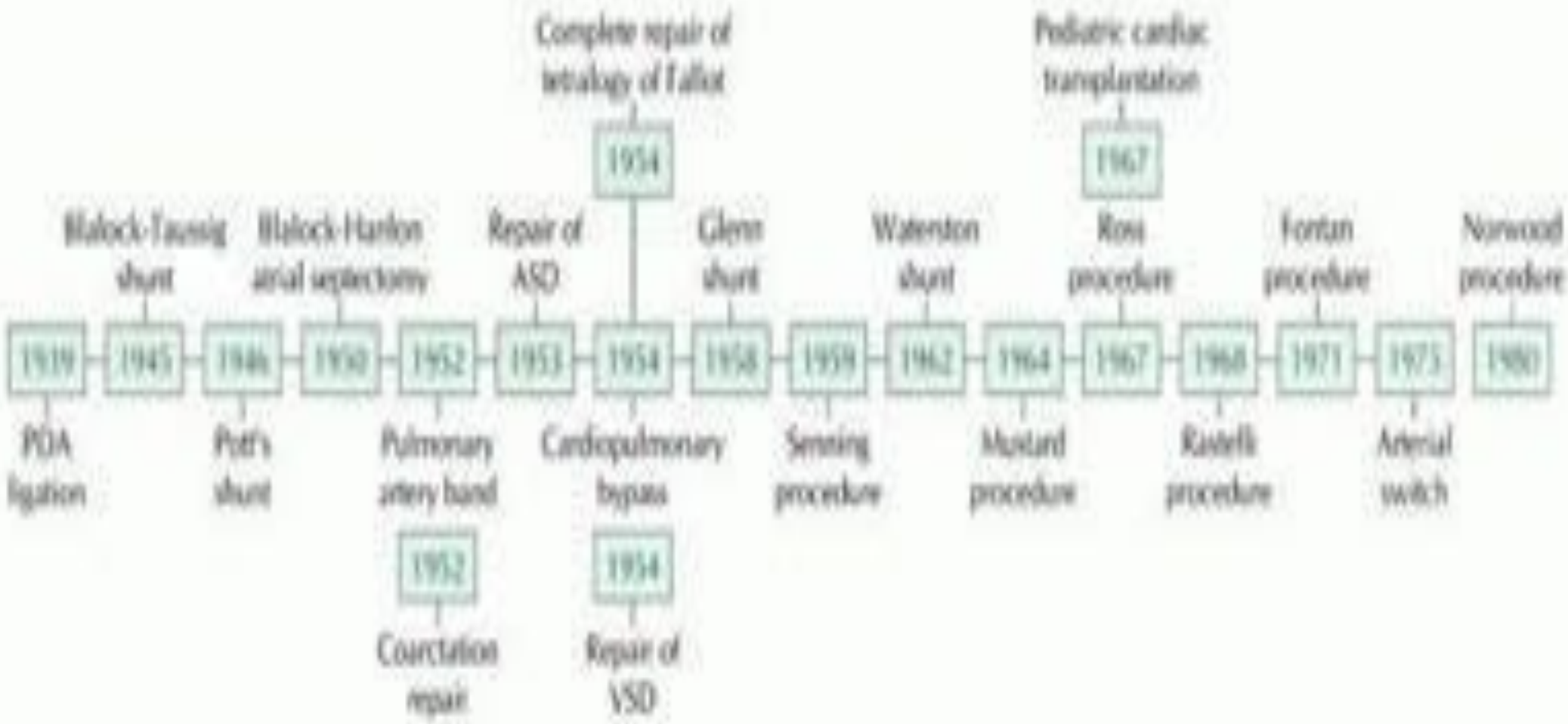
Complete repair of tetralogy of Fallot
1954
Pediatric cardiac transplantation
1967
Blalock-Taussig shunt
1945
Blalock-Hanlon atrial septectomy
1950
Repair of ASD
1953
Glenn shunt
1958
Waterston shunt
1962
Ross procedure
1967
Fontan procedure
1971
Norwood procedure
1980
1939
1946
1952
1954
1959
1964
1968
1973
PDA ligation
Potts shunt
Pulmonary artery band
Cardiopulmonary bypass
Senning procedure
Mustard procedure
Rastelli procedure
Arterial switch
1952
Coarctation repair
1954
Repair of VSD

cardiopathies « réparées »

- Coarctation
- sténose aortique
- tétralogie de Fallot
- transposition des gros vaisseaux

Frans Lanting/Minden Pictures

coarctation aortique : sténose le plus souvent au niveau de l'isthme aortique.

incidence de la coarctation 4 pour 10.000 naissances vivantes soit 5–8% des enfants ayant une cardiopathie congénitale.

- diagnostic peut être tardif si bien que son incidence est sous estimée.
- L'évolution naturelle: très mauvaise
- espérance de vie d'une coarctation non opérée est de 35 ans et que 90% des patients meurent avant l'âge de 50 ans .(2)
-

coarctation

- NON fait partie d ‘un spectre (lésions du cœur gauche associant de façon variable anomalies mitrales, petite voie sous aortique, CIV et dans plus de 50% des cas une bicuspidie aortique)
- fréquemment associée à une hypoplasie diffuse de l’arche aortique et de l’isthme aortique .

Noenatal coarctation : differents phenotypes

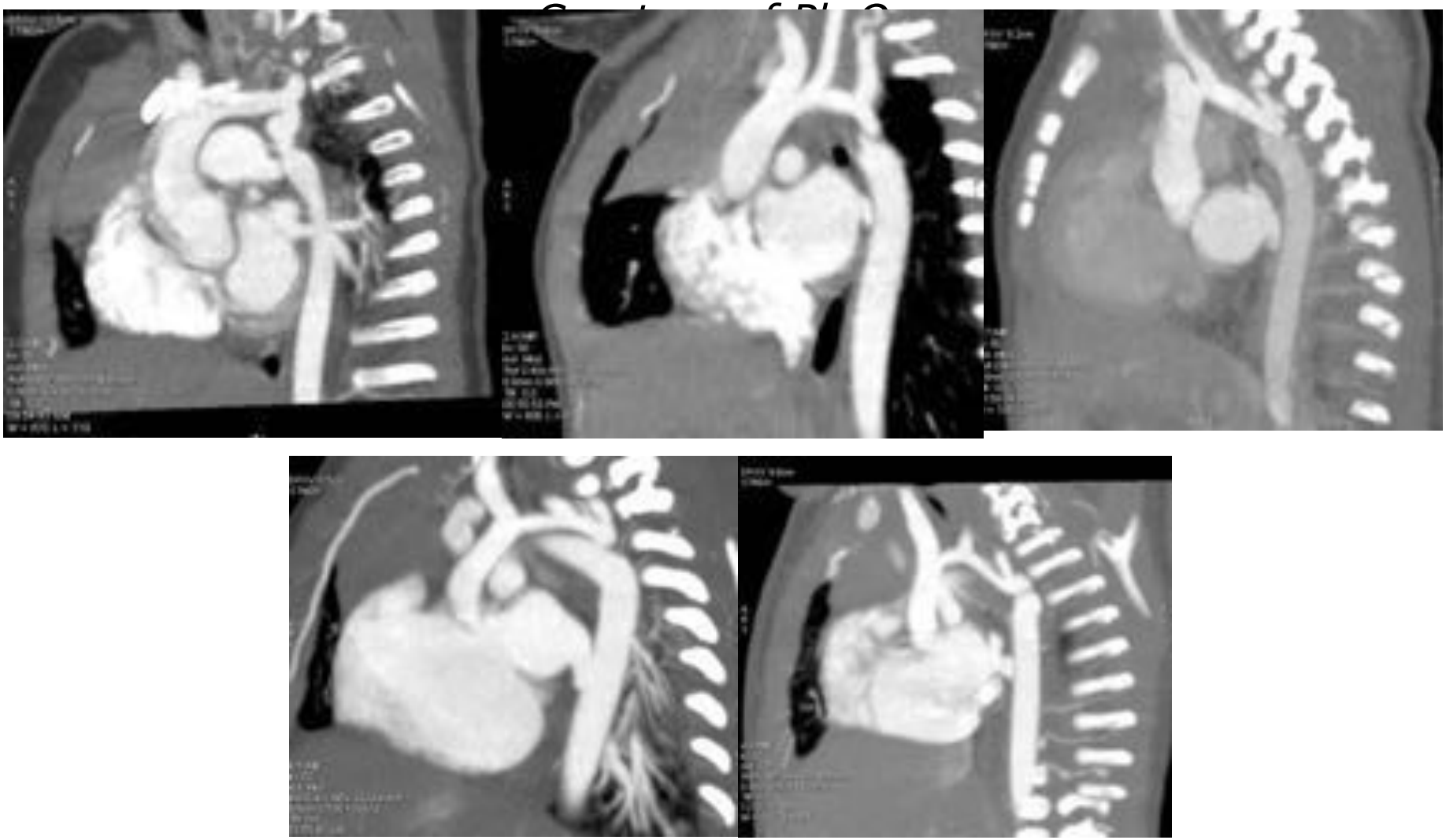

Ductal tissue and shelf in the ishtmus

Associated lesions and spectrum of Left heart obstruction

- Thoracic Coarctation of the aorta (CoA) : 5-8% of all congenital heart defects.
- isolated defect or various other lesions

- VSD and duct and hypoplasia of transverse aorta
- bicuspid aortic valve 27 - 46 %
- ventricular septal defect (VSD)
- Patent Ductus Arteriosus (PDA).
- Subvalvular Aortic Stenosis (AS)
- Aberrant right Subclavian Artery (SCA).
- Parachute mitral valve. 2 -8 %
- Supravalvular aortic stenosis 5 (Wiliams syndrome
- Transposition of the Great Arteries (TGA). 9 %
- DORV 4 %
- univentricular heart 4 %

Severe form of obstruction with hypoplastic left heart

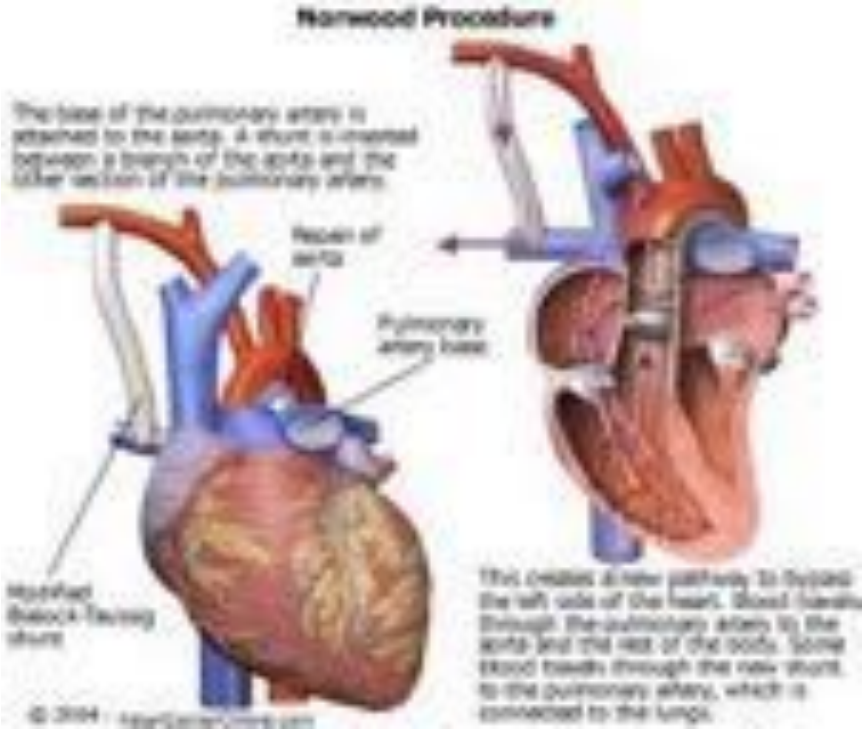

Operated Coarctation

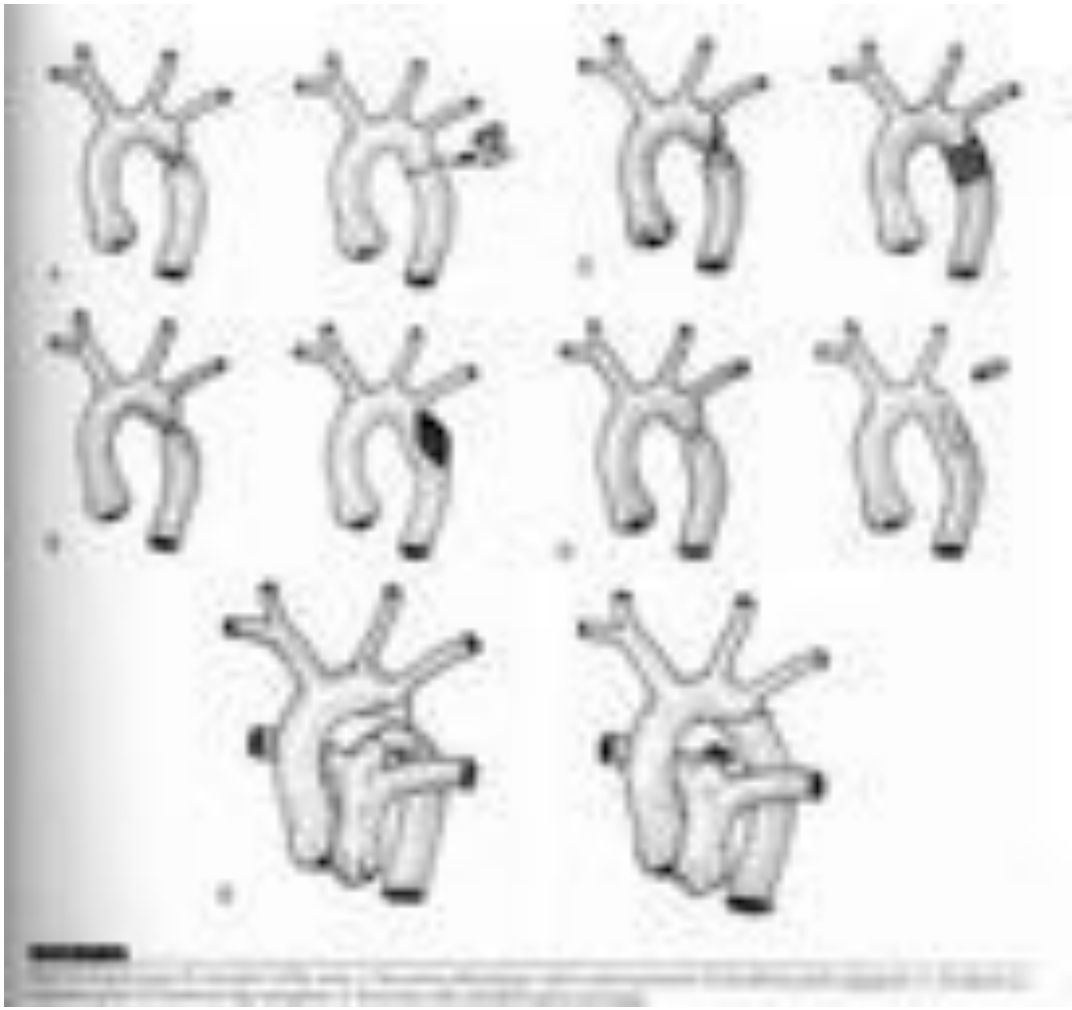

An end-to-side anastomosis.

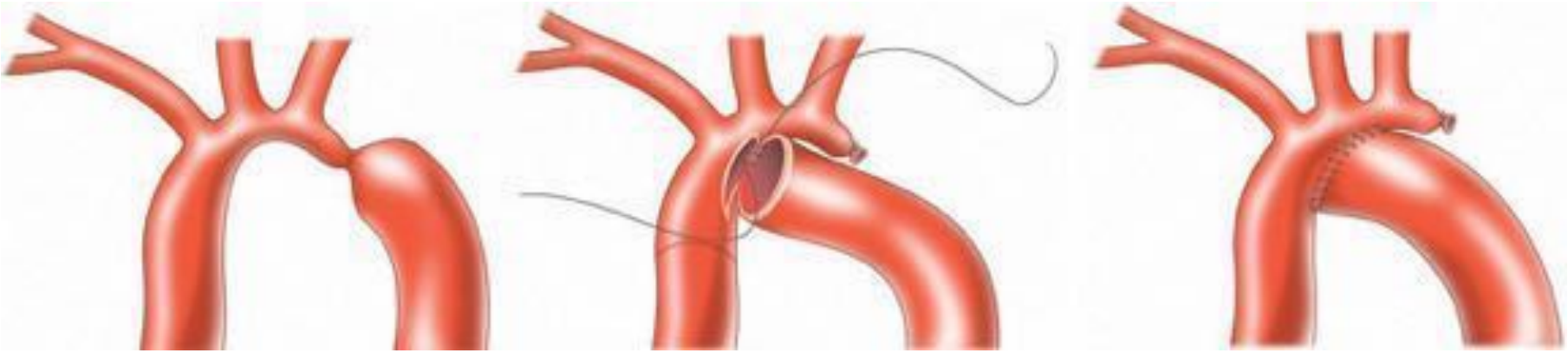

Rakhra S S et al. Interact CardioVasc Thorac Surg 2012;icvts.ivs301

INTERACTIVE CARDIOVASCULAR AND THORACIC SURGERY

Circulation.

Coarctation : spectrum of Left Heart obstruction

Abulhosn ,Circulation. 2006

In older children or adults:coarctation induced lesions

- collateral circulation

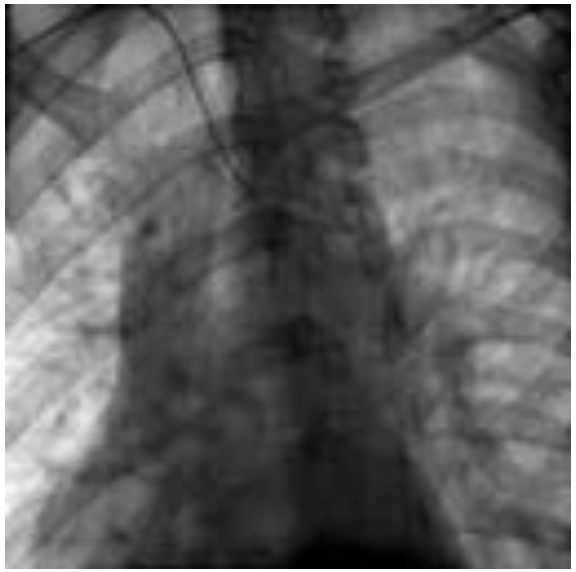

-

- aortic aneurysm (10 % at 20 years, 20 % at30 years)
- pre Coa due to hypertension (and bicuspid aortic valve)
- post Coa : mycotic aneurysm , post stenotic jet
- premature coronary artery disease (not an independant risk factor (*Roifman Circulation. 2012)*

Recoarctation : stenting

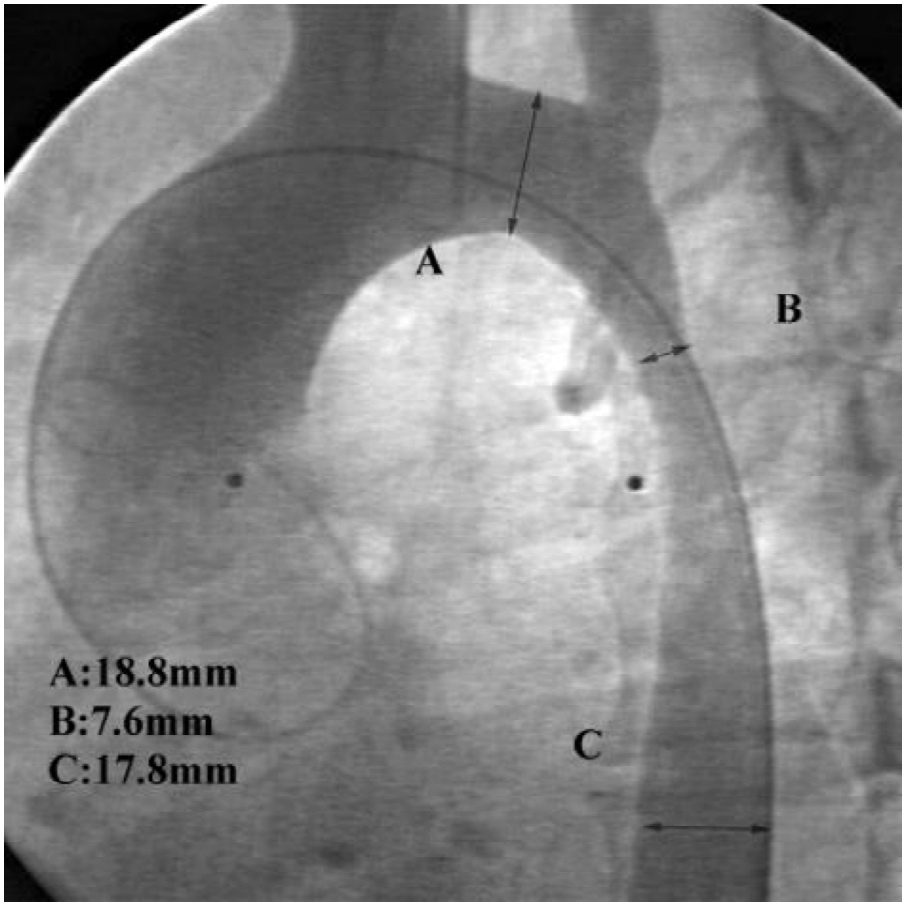

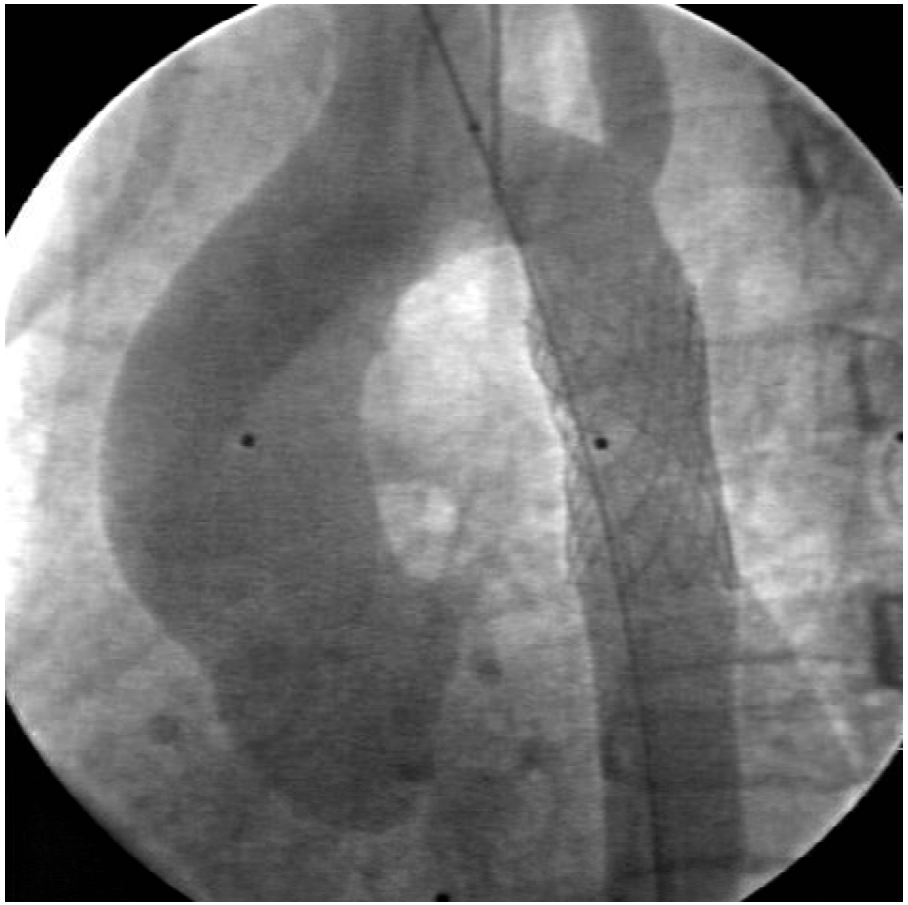

Operated Coarctation : subclavian flap procedure

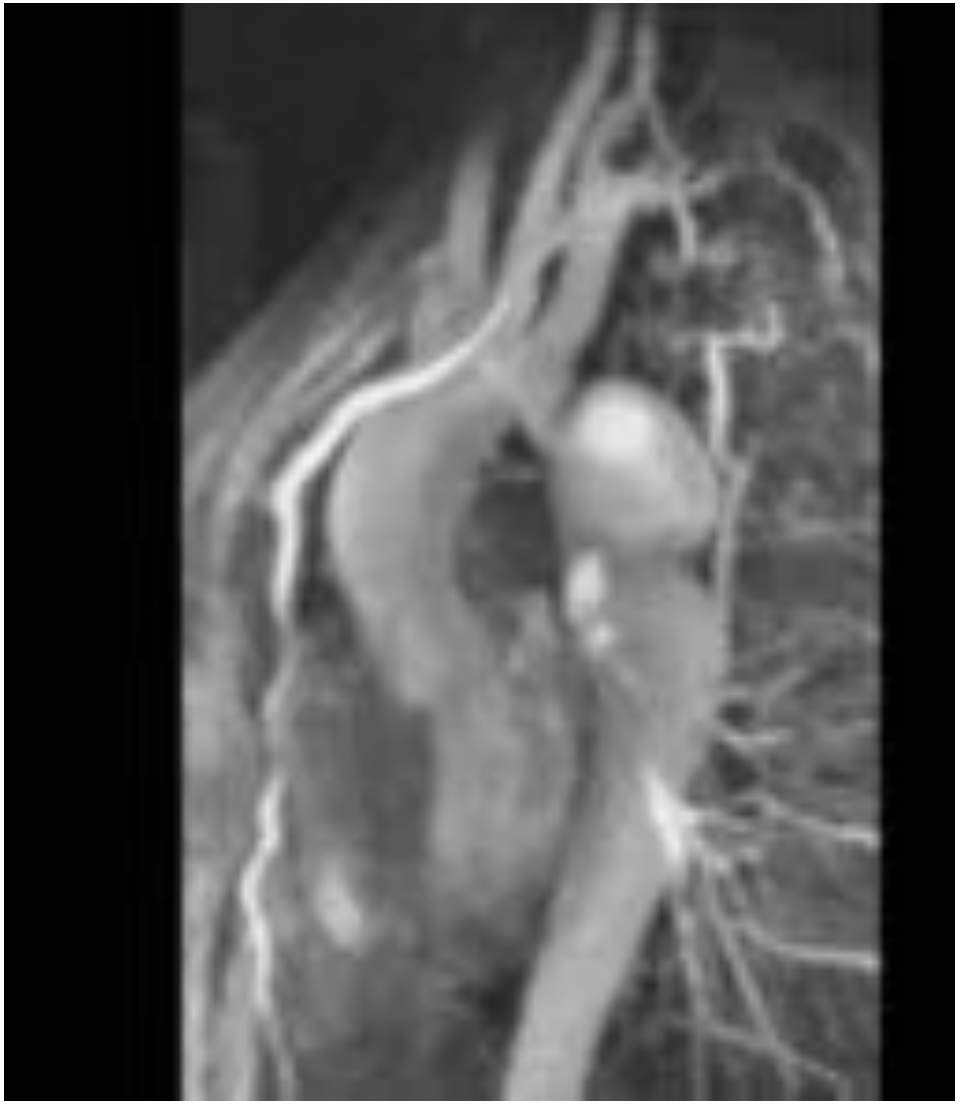

Preop

Post op

CT Scanner Aortic Arch

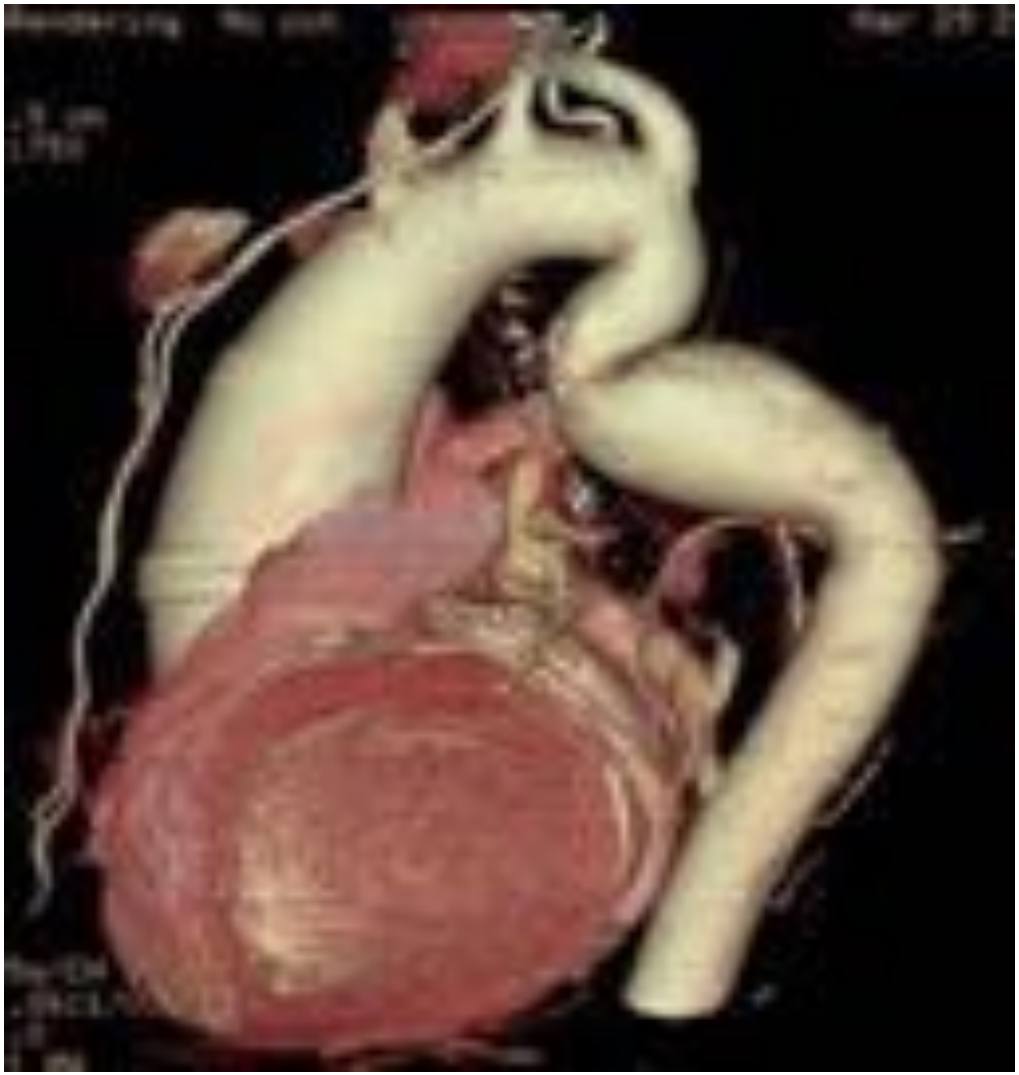

Pregnancy 36 weeks

Bicuspid aortic valve only?

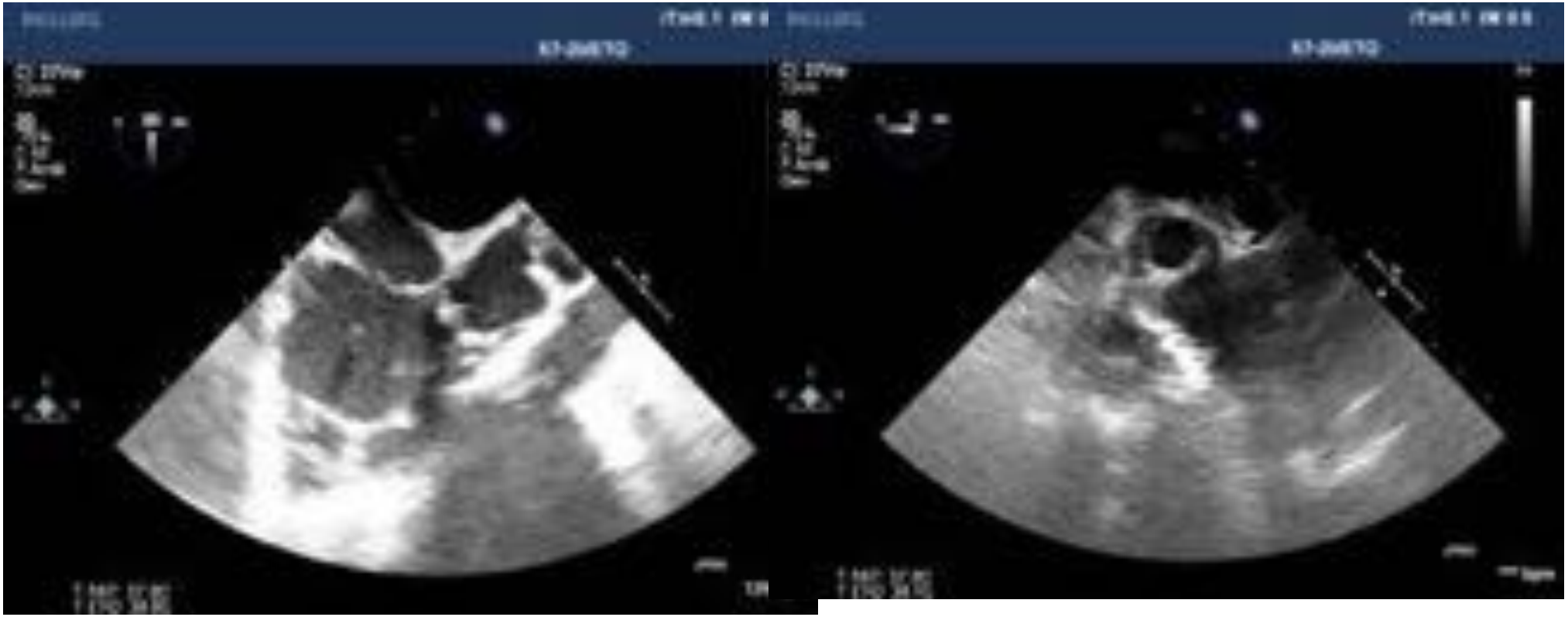

Hypertension after repair of aortic coarctation - A systematic review.

- 26 articles
- median prevalence of hypertension late after anatomically
- satisfactory coarctation repair 32.5% (range 25-68%)

  - Surgical " scar"
  - Anatomical predisposition?
  - Genetic?
  - Premature aging?

Canniffe C, Ou P, Walsh K, Bonnet D, Celermajer D. Int J Cardiol. 2012

Canniffe C, Ou P, Walsh K, Bonnet D, Celermajer D. Int J Cardiol. 2012

Recurrence of familial Left heart osbtruction: Continuum

HLHS

bicuspid valve

coarctation

Wiliams syndrome : diffuse pathology of vascular tree

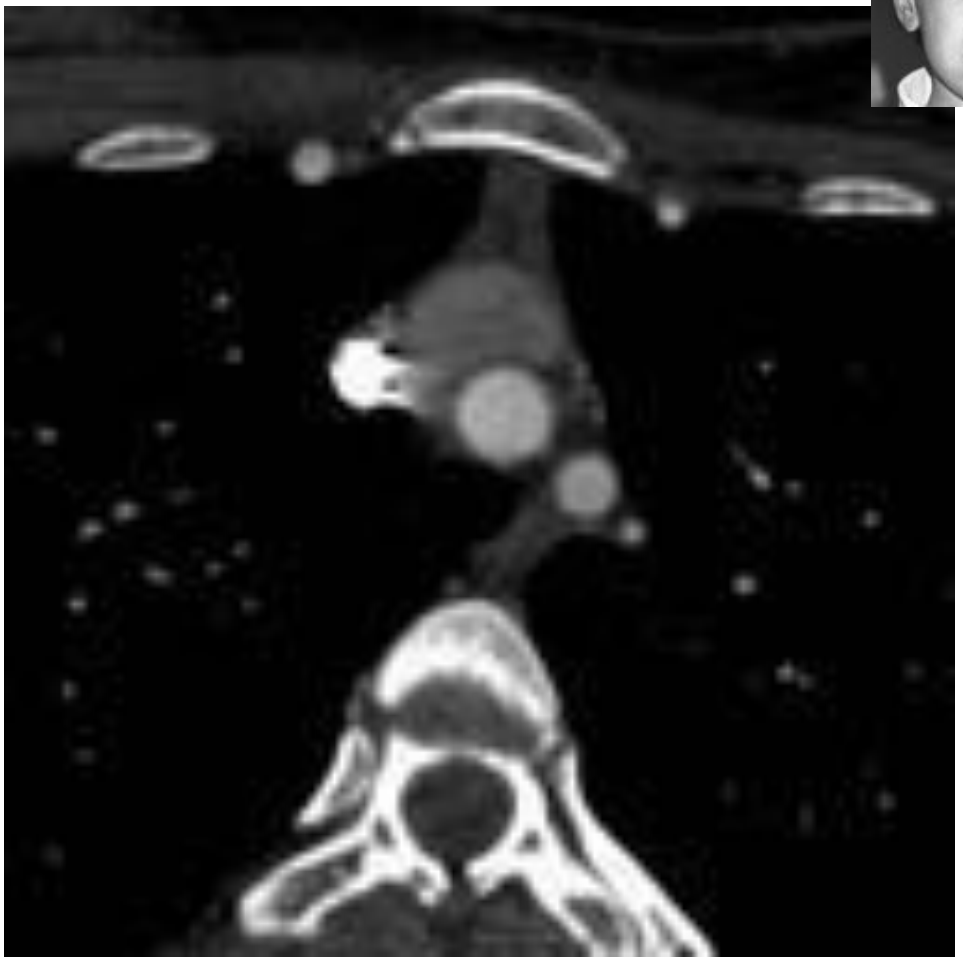

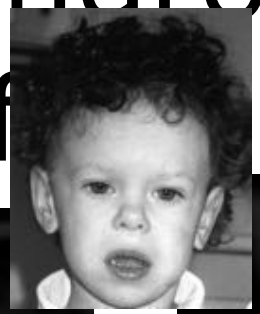

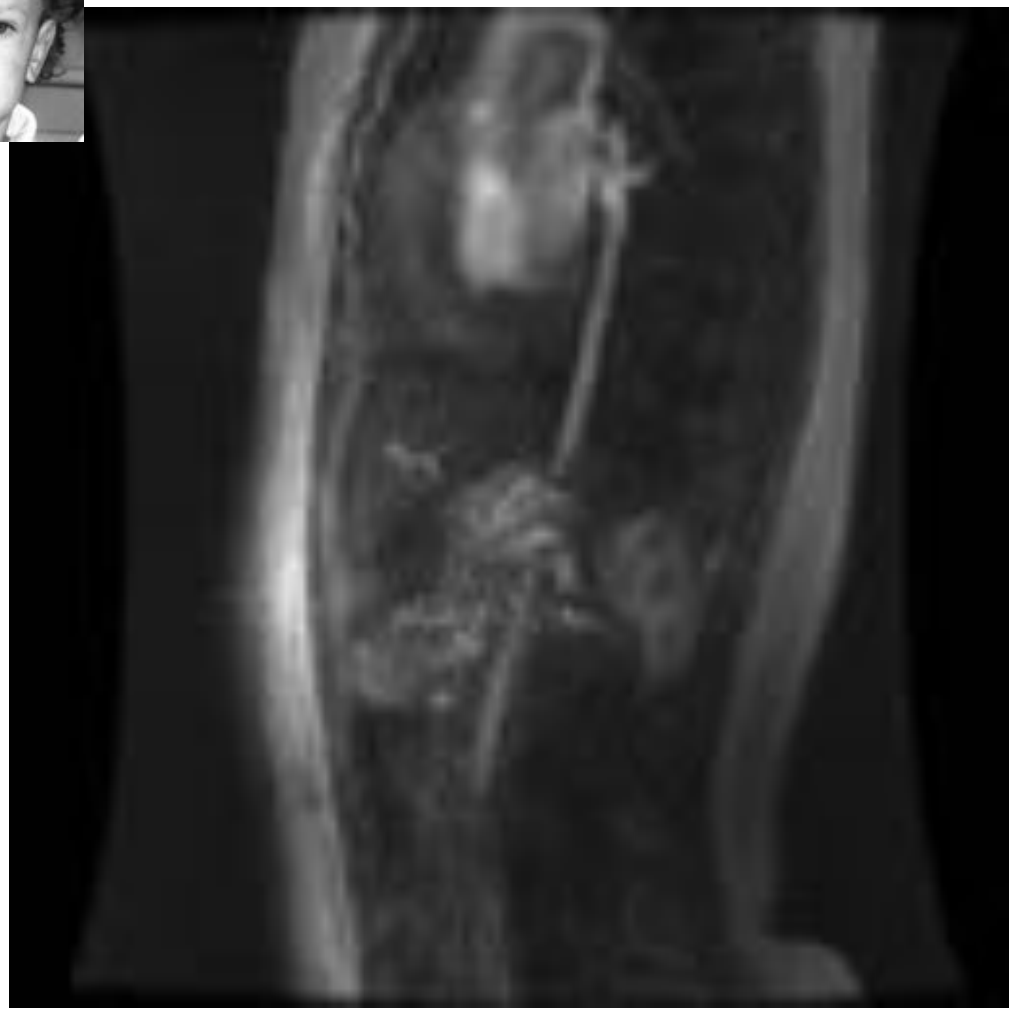

Turner : Hypertension, operated coarctation , bicuspid aortic valve high risk dissection: 2,5cm2/m2

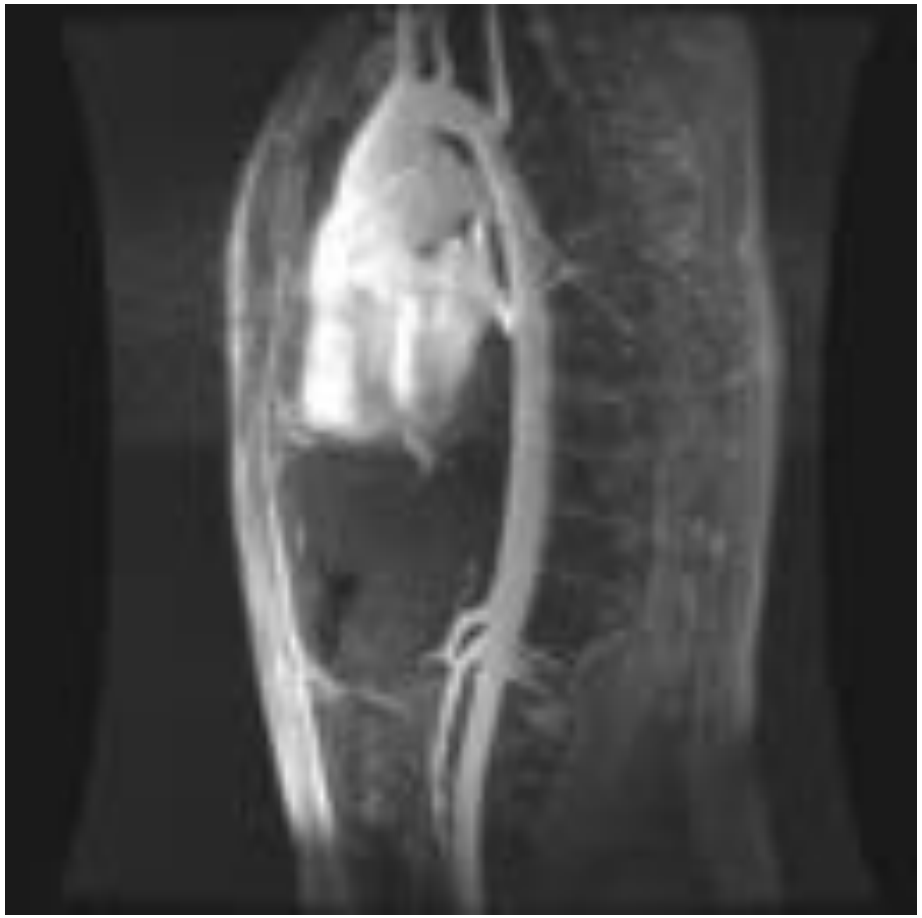

Carlson M, Circulation. 2012

Alagille syndrome

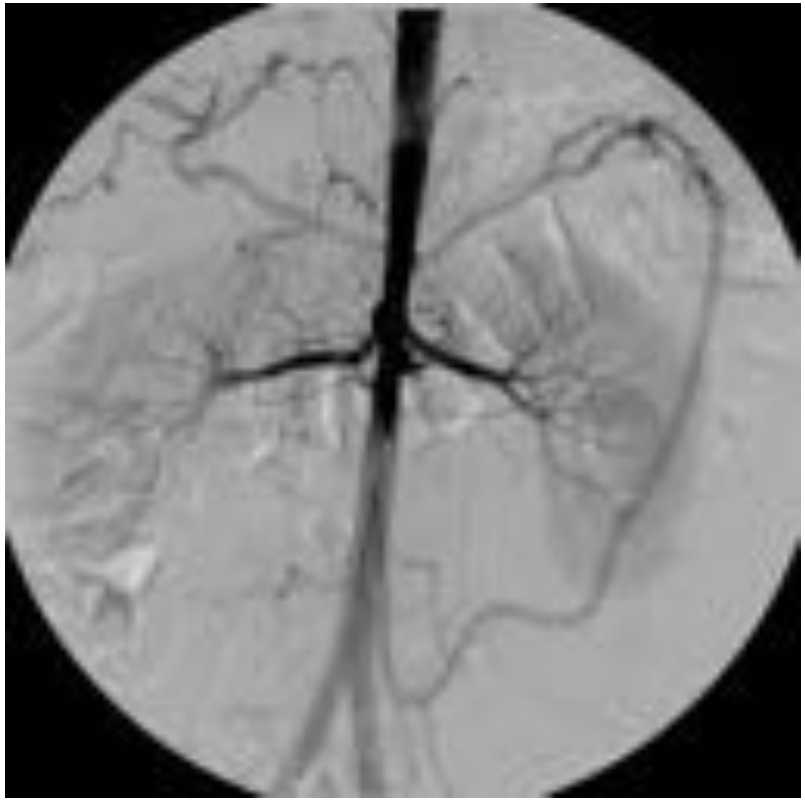

Salem JE, Bruguiere E, Iserin L, Guiochon-Mantel A, Plouin PF..
J Hypertens. 2012

Does it matter???

Death in unoperated coarctation

50 % before 32 years

But survival descrived as very different from the normal population

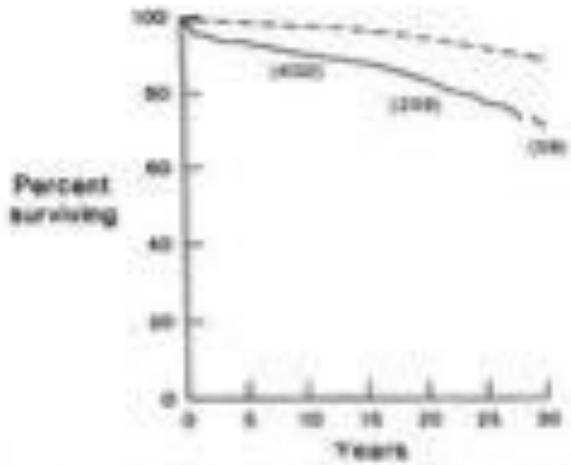

Cohen M, Circulation. 1989

Causes of Late Deaths After Pediatric Cardiac Surgery : A Population-Based Study

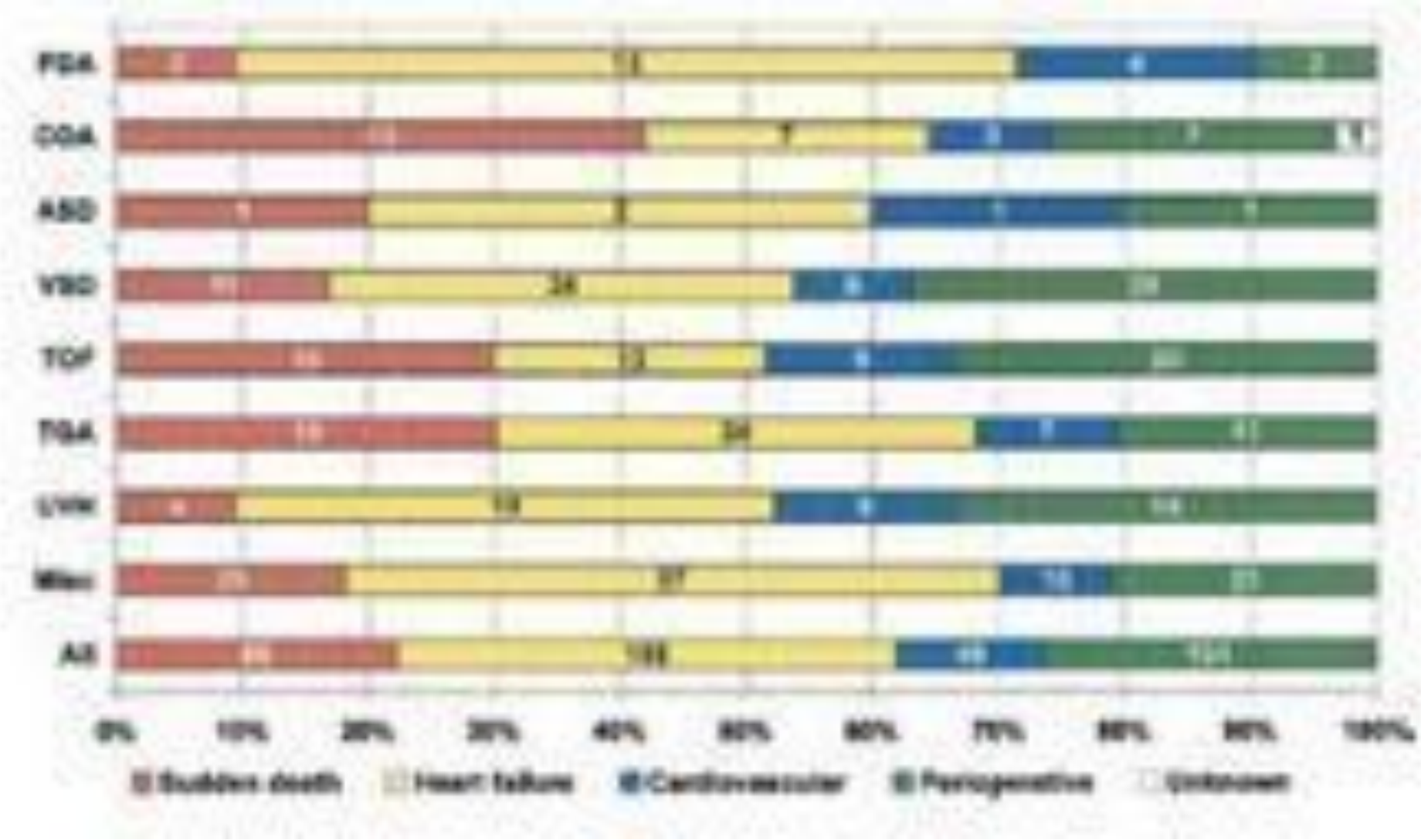

J. Am. Coll. Cardiol. 2007 Nieminen,

Pediatric Cardiac Surgery in adults : A Population-Based Study



J. Am. Coll. Cardiol. 2007 Nieminen,

Causes of Late Deaths After Pediatric Cardiac Surgery : A Population-Based Study

13 Coarctation patients died suddenly (42%)

- 5 (38%)untreated valvular aortic stenosis .
- 4 cases ruptured or dissected aorta.

J. Am. Coll. Cardiol. 2007 Nieminen, Jokinen,Sairanen,

Experimental coarctation in rabbits by dissolvable suture

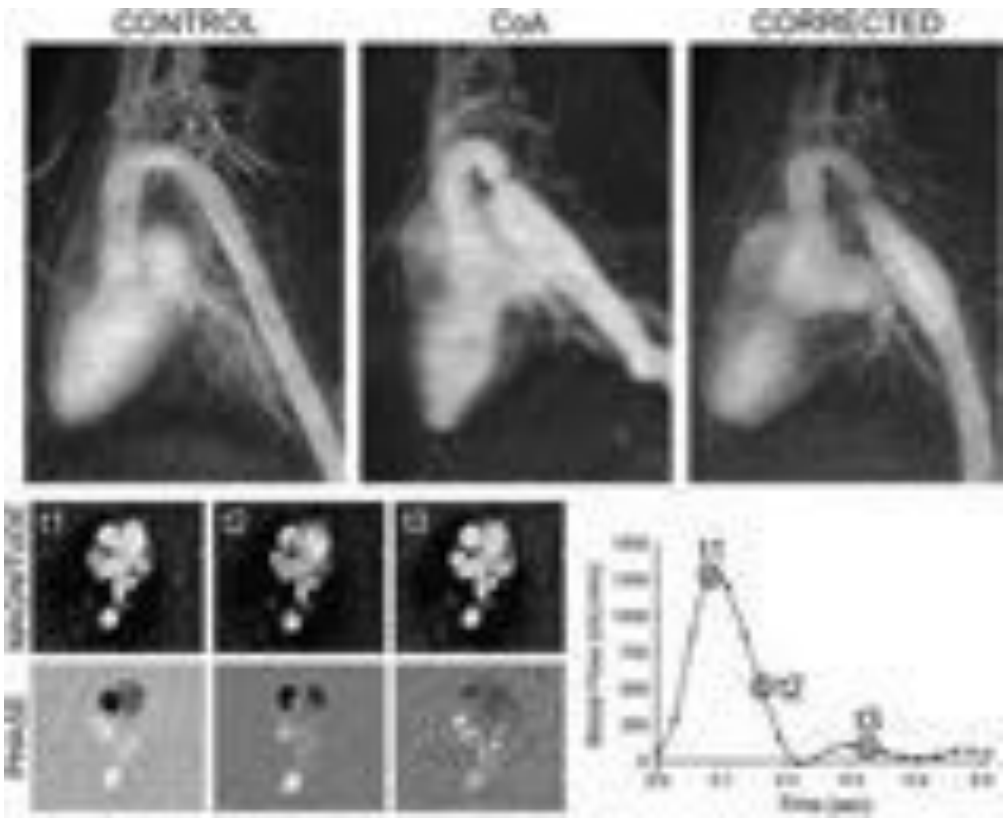



Menon et al Journal of Pharmacological and Toxicological Methods 65 (2012)

Circumferential Aortic Strain and Distensibility and Age

Early alteration of aortic strain and distensibility in AS individuals

Sensitive markers of vascular alteration

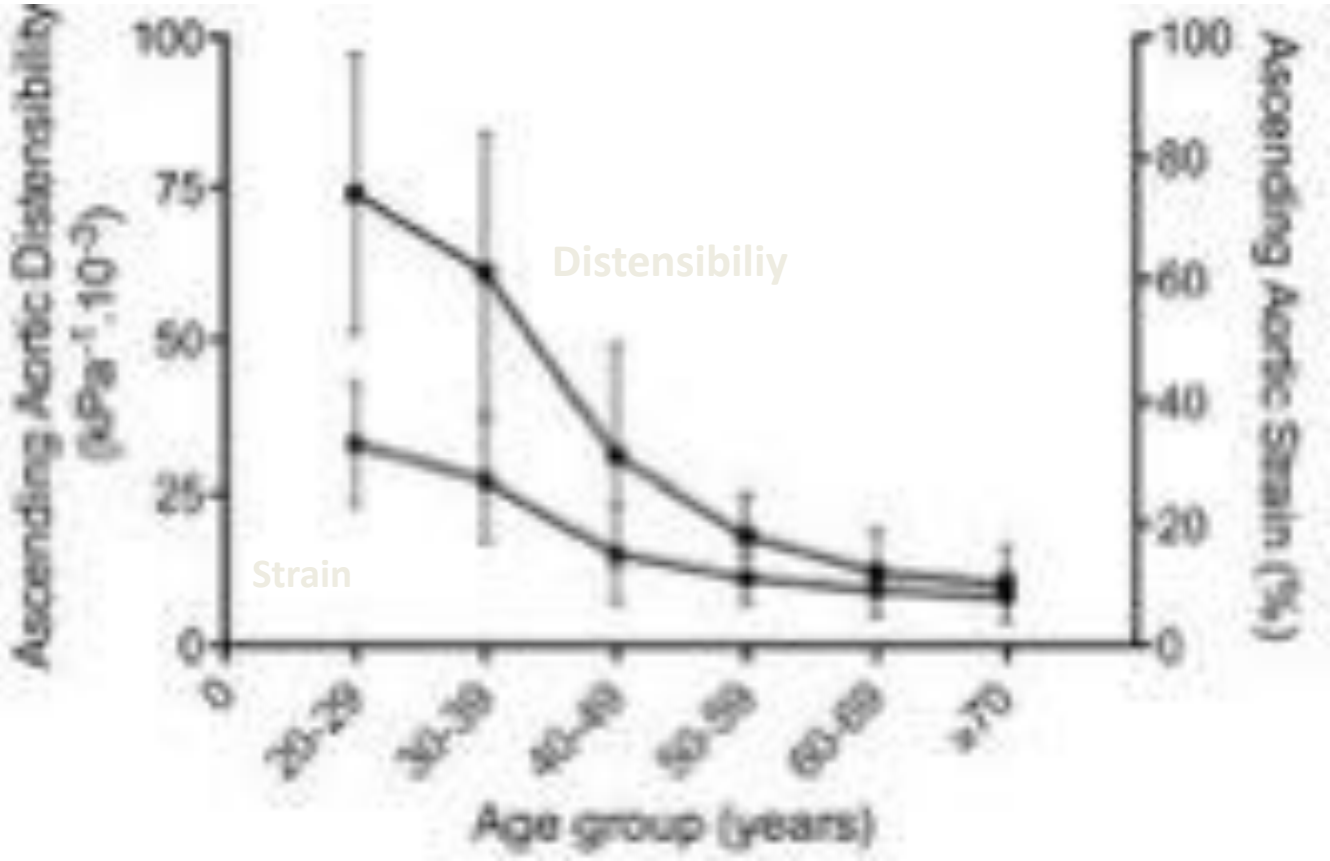

Redheuil A. et al. Hypertension 2010

Proximal aortic stiffness and Age

Cf-PWV vs. Aortic arch PWV with MRI

Cf-PWV
Tonometry

Arch PWV
MRI



Redheuil A. et al. Hypertension 2010

Aortic Arch PWV

cf-PWV tonometry vs. Arch PWV CMR

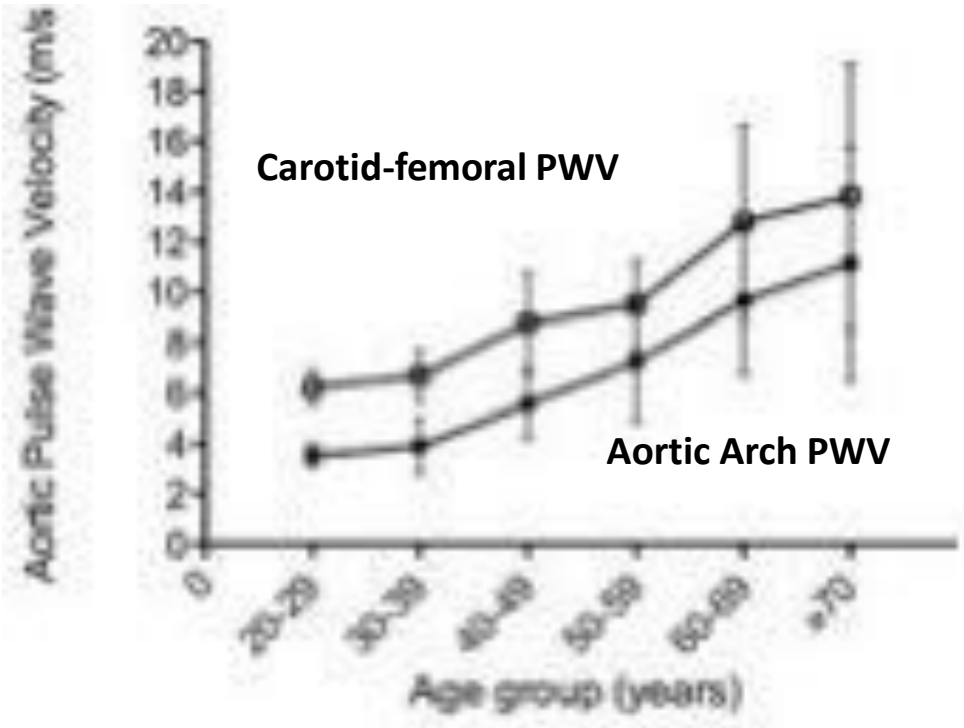

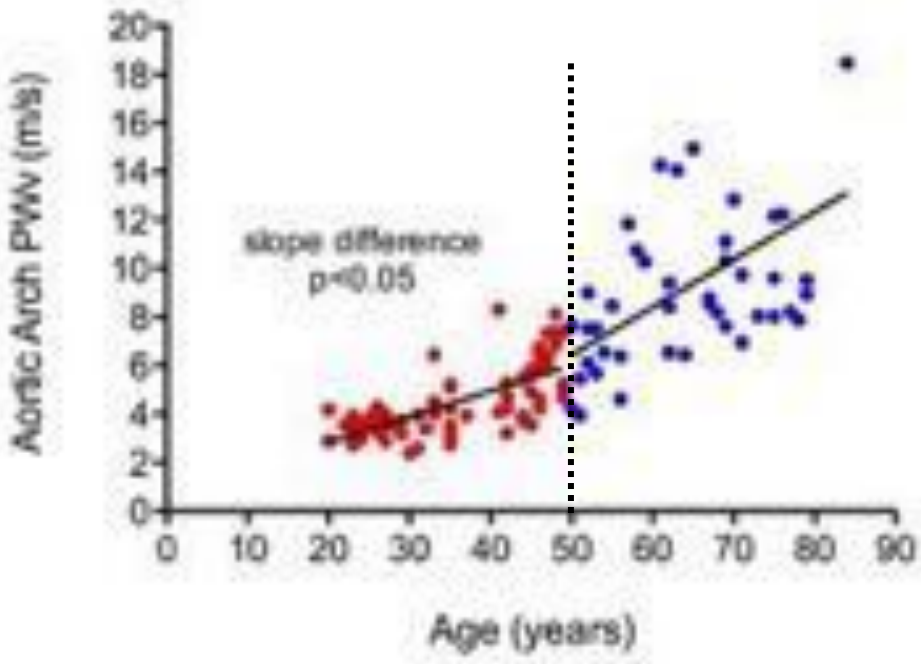

Redheuil A. et al. Hypertension 2010

Morphology of the Aortic Arch and Aging

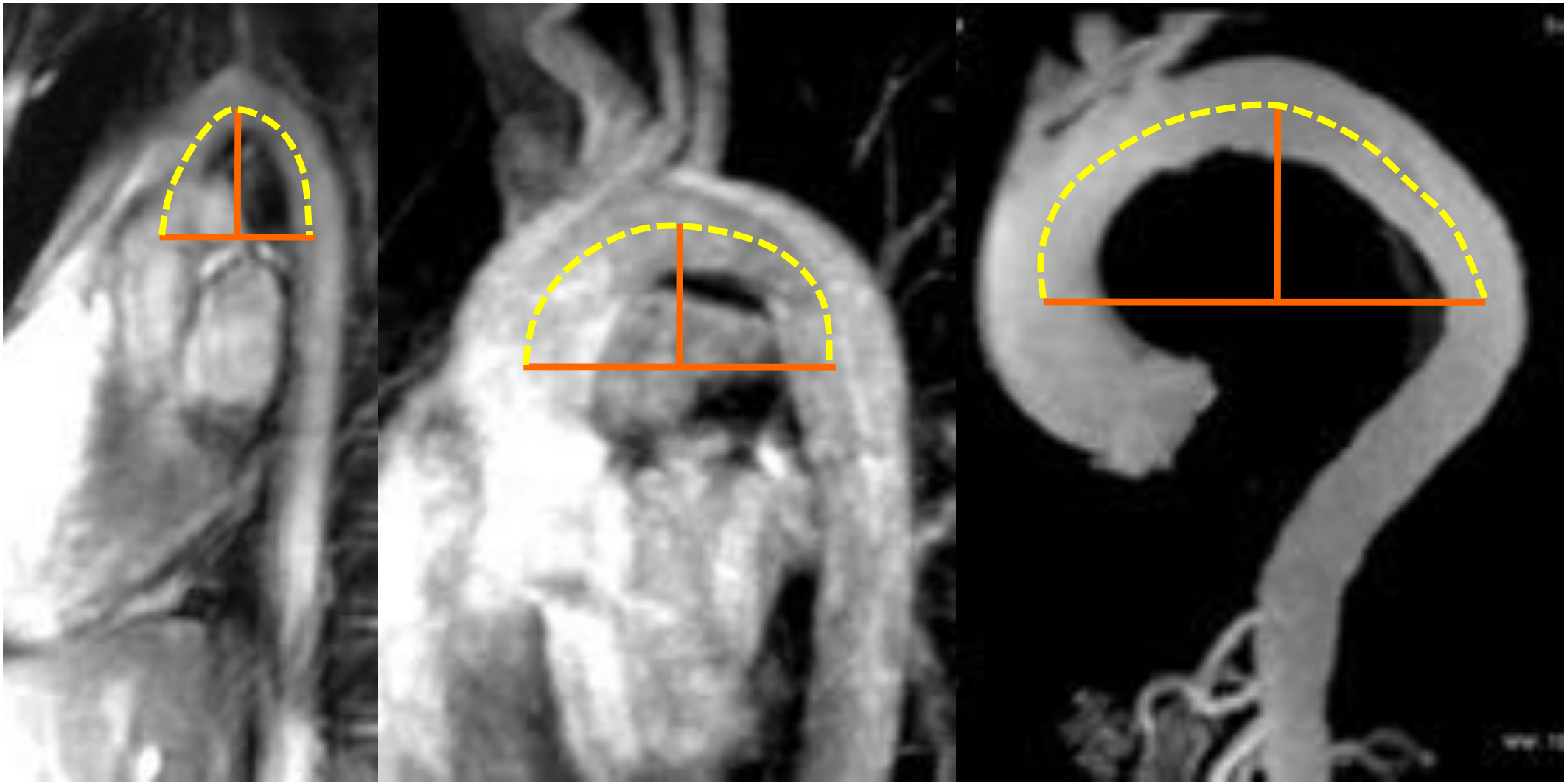

Boy 16 yrs | Man 40 yrs | Man 81 yrs

Redheuil A, JACC Sep 2011

Angular (Gothic) Aortic Arch Morphology

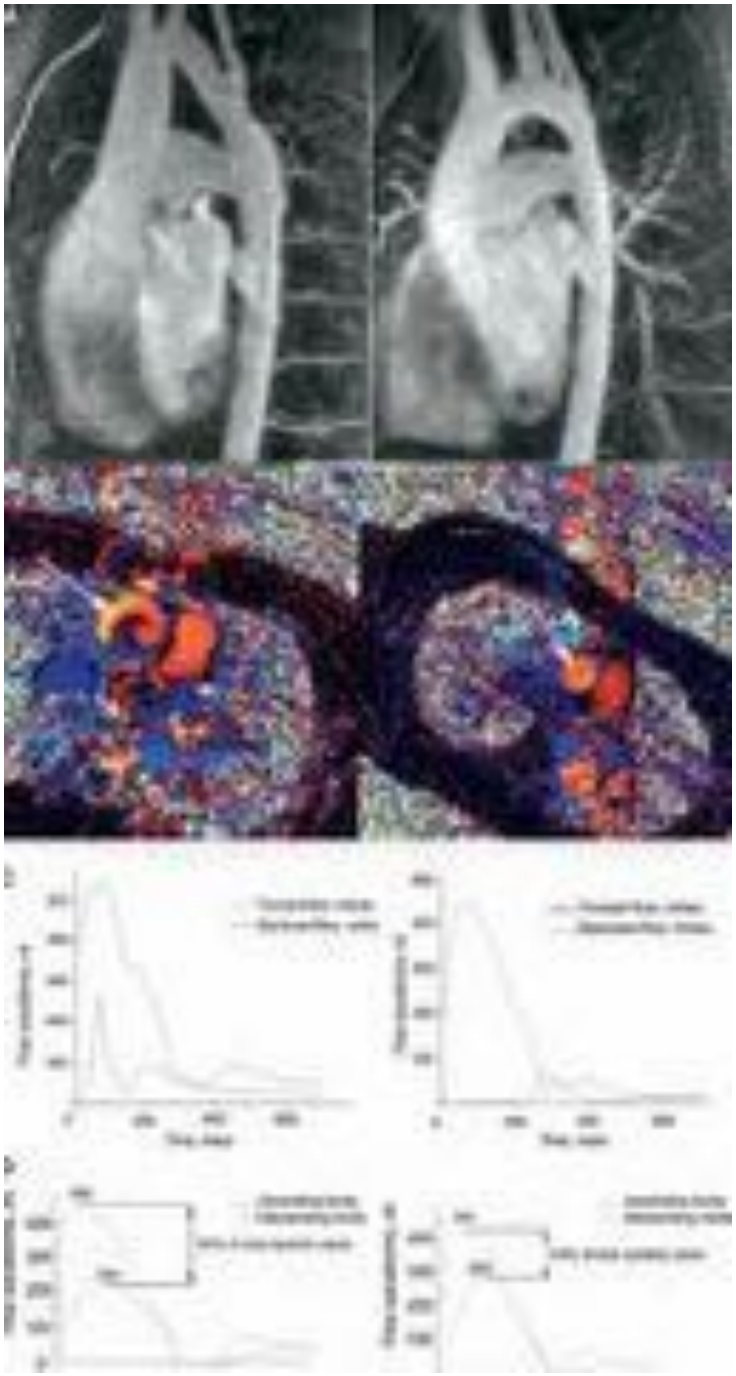

Coarctation : a premature aging situation?

Ou P, J Thorac Cardiovasc Surg. 2008

In conclusion coarctation is

- Not a single defect in infancy
- A complex lesion in adulthhod
- Associated with numerous lesions
- Requires a life long follow up

Etude échographique bicuspidie decouverte chez jeunes hommes service militaire (n=66)
50 % aorte normale

7,5% 19,6% 15% 43%

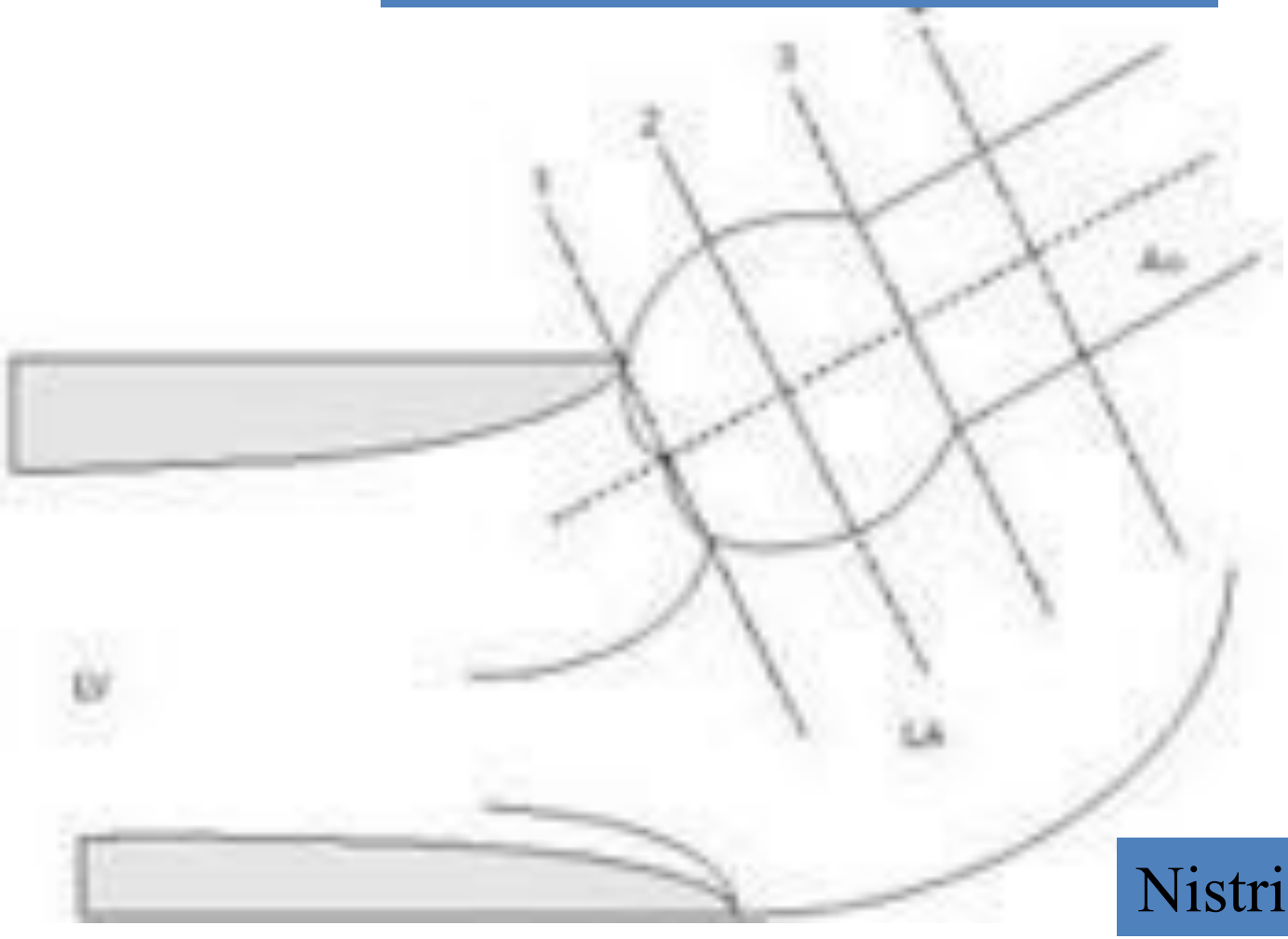

Nistri, heart 1999

spectre

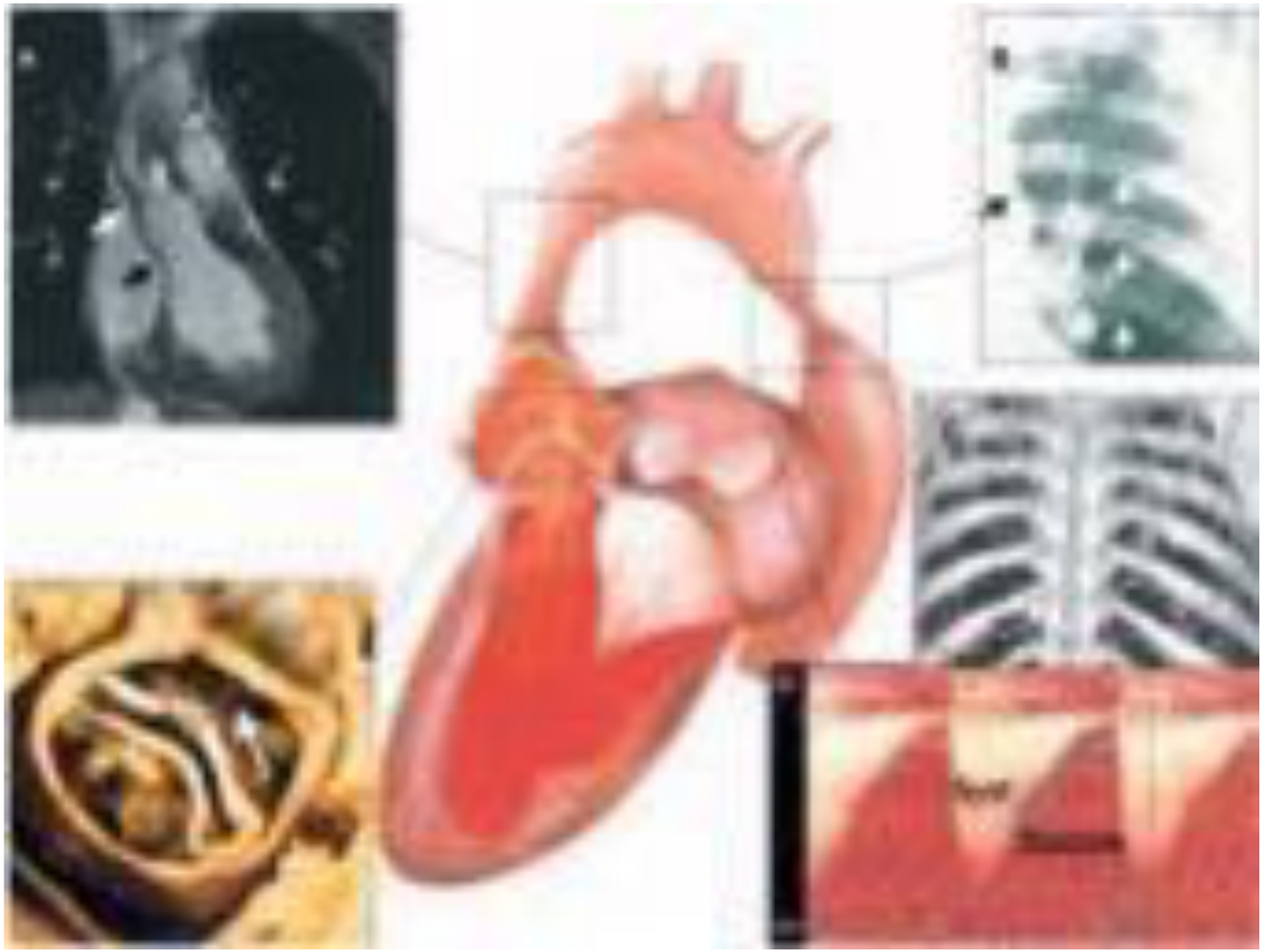

- Les dilatations aortiques ont les même lésions histologiques quelques soit l'étiologie
- Mais les seuils sont différents pour autoriser la grossesse
  - Marfan 40mm
  - Turner 25mm/m2
  - Bicuspidie, coarctation ???
  - Fallot , APSO ???
- Evaluation avant la grossesse, imagerie +++
- Surveillance, très vigilante à partir du 2è trimestre
- Collaboration multidisciplinaire à tous les stades

recoactation

- Habituellement accessible à dilatation avec stent

Morphologie de l'arche aortique

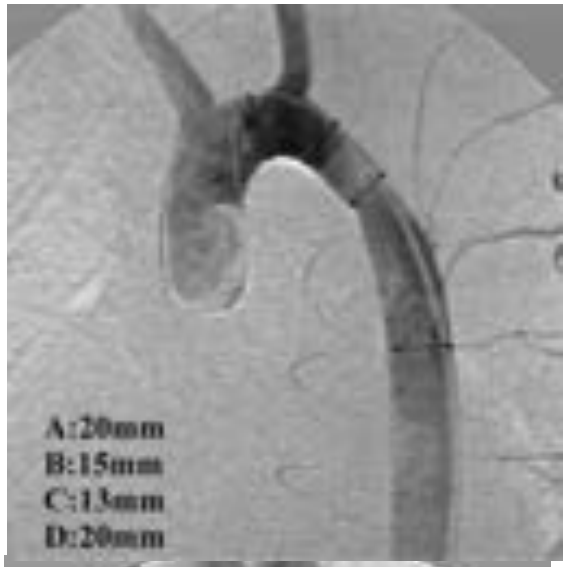

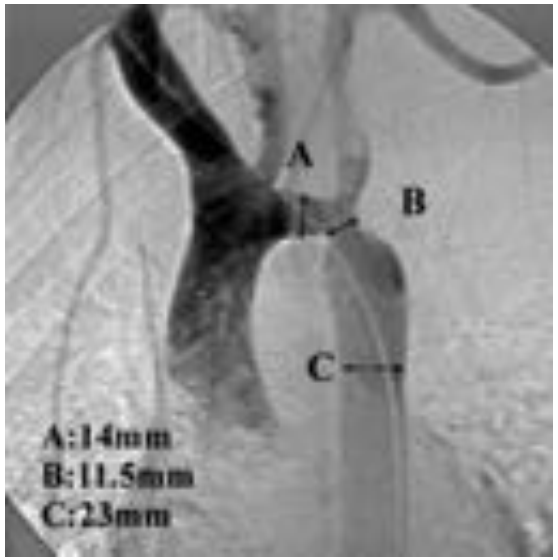

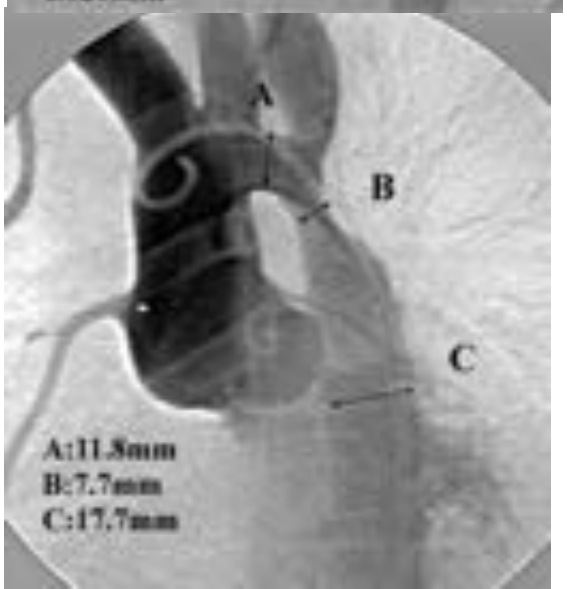

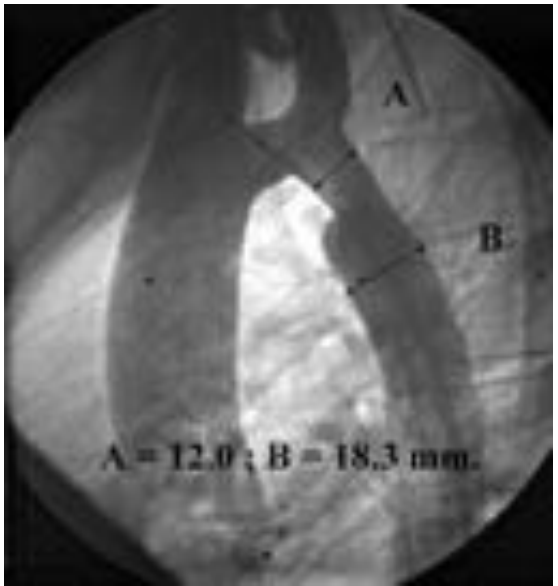

HEGP

Traitement interventionnel de la coarctation et de la recoarctation de l'aorte chez l'adulte

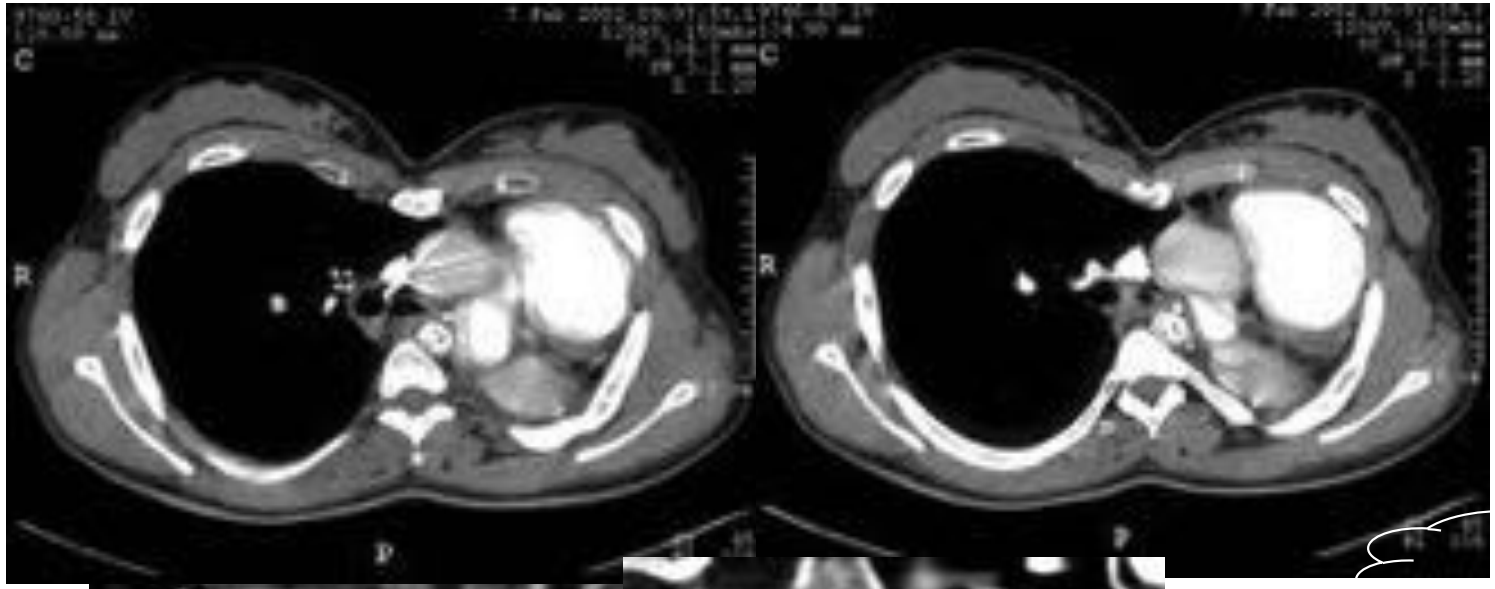

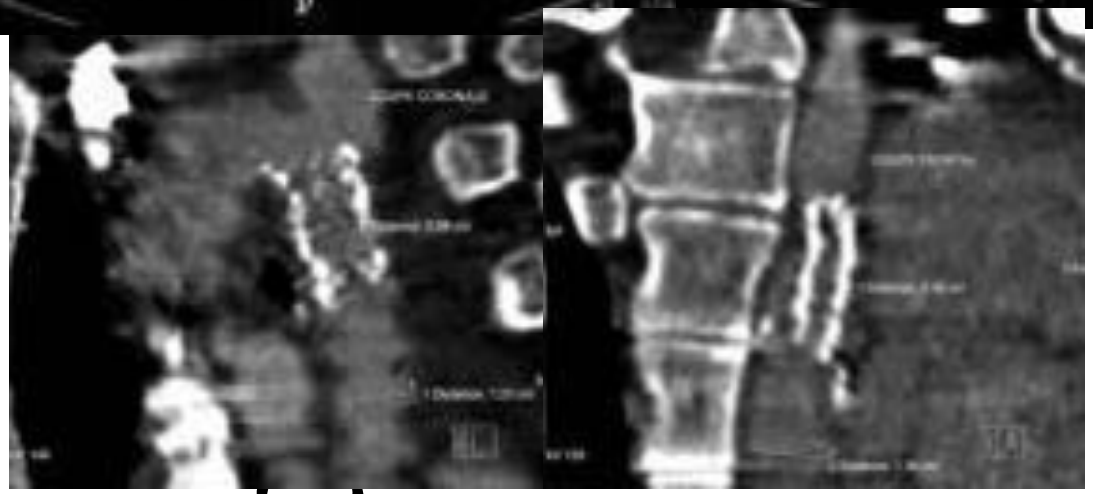

des jolies images!

Complications: fracture du stent

Mortalité due à une chirurgie tardive?

- même après une chirurgie effectuée vers âge de 5 ans, la survie estimée est de 91% à 20ans et de 80% à 40 - 50 ans après l'opération.

70% des décès tardifs sont liés à des complications cardiovasculaires

recoarctations, anévrisme aortique, dissections, association avec une valve aortique bicuspide, coronaropathie précoce et accidents vasculaires cérébraux ;

Problème le plus fréquent : HTA sans obstacle

- Traitement médical aggressif compte tenu des complications potentielles
- à long terme environ 30% sont des hypertendus permanents de repos,
- 30% ont une HTA d'effort, correspondant souvent avec des mesures de pressions ambulatoires élevées
- , et 30% ont une pression normale au repos et à l'effort

Sténose aortique
intervention de Ross

Pathologies obstructives du cœur gauche

Tableau complet : syndrome de Shone
Sténose mitrale
Anneau supra valvulaire mitral
Sténose sous aortique
Bicuspidie aortique
coarctation

Formation des valves semilunaires : valves bicuspides

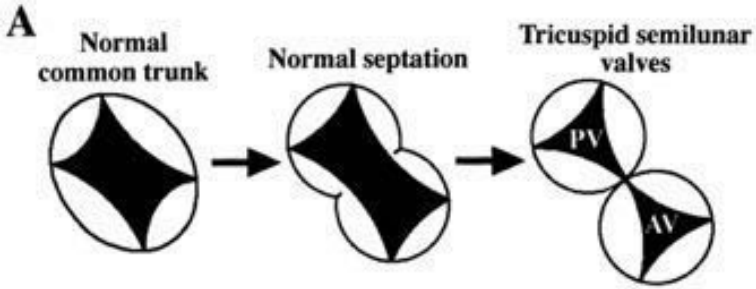

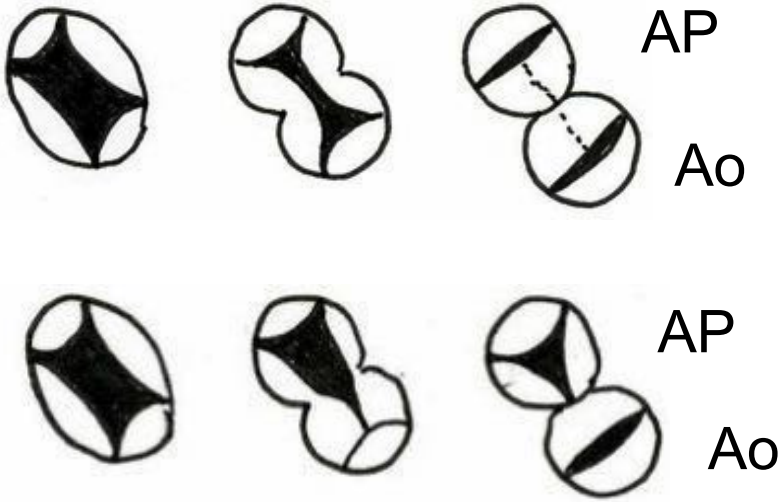



Bicuspidie horizontale

Bicuspidie verticale

Unicuspid unicommissural aortic valves

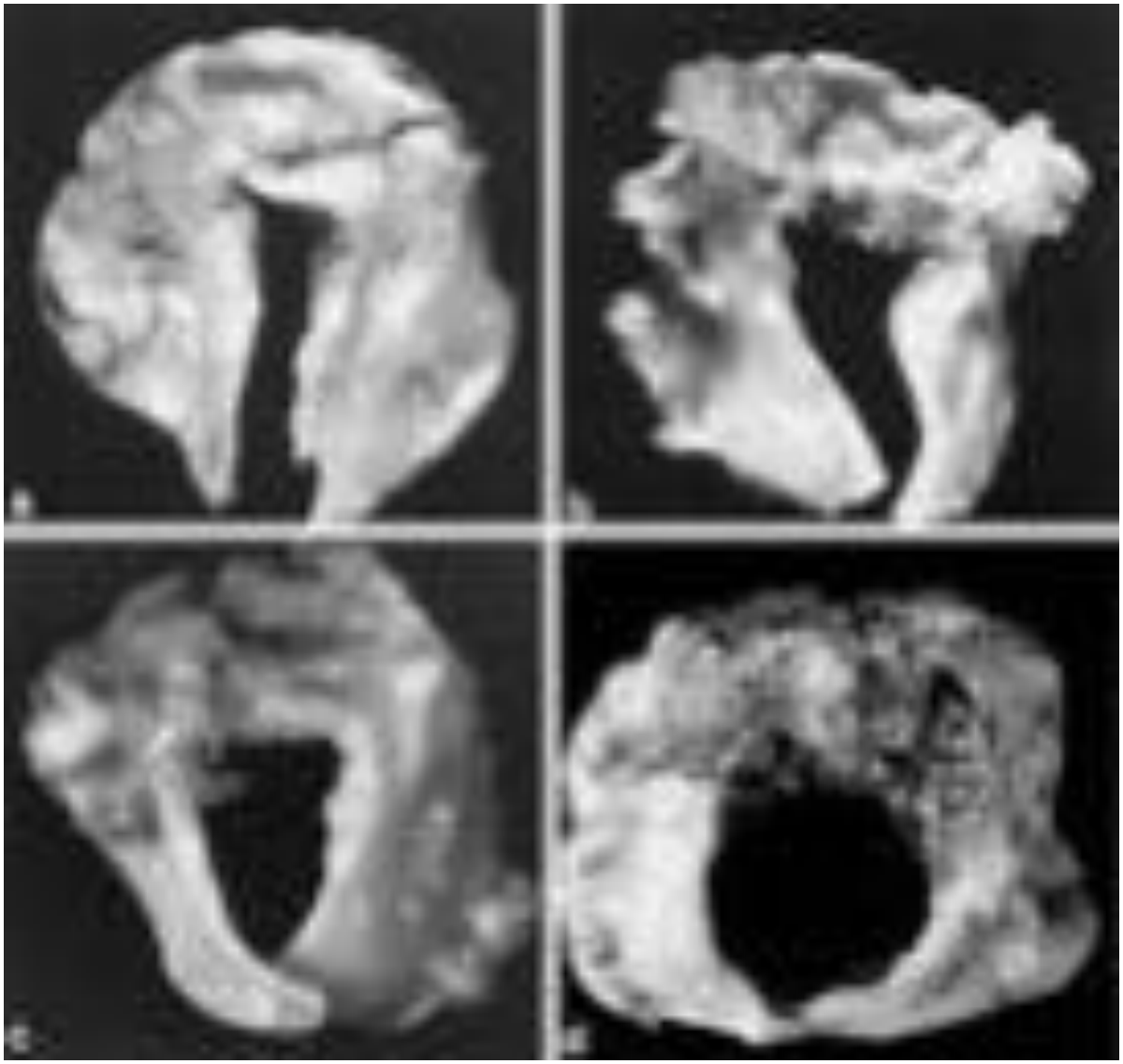

Roberts, W. C. et al. Circulation 2005;111:920-925

American Heart Association®

Learn and Live℠

Morphotypes de bicuspidie

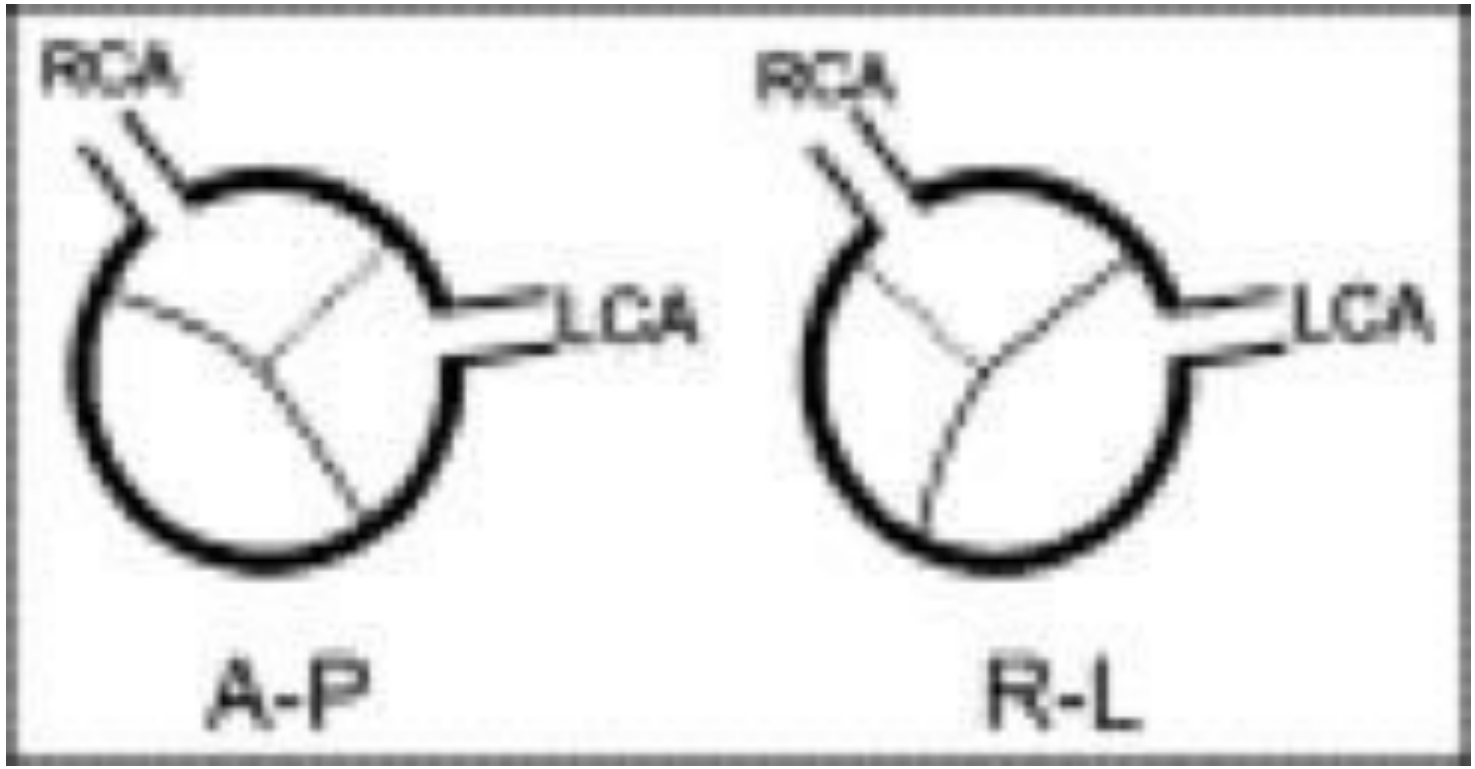

Fusion cusp D et G
Plus fréquente X4
moins de complications valvulaires
plus de rigidité aortique (echo)
plus souvent associée à la coarctation

Schaefer Am J cardiol 2007
Fernandez Jacc 2004

Complications purement valvulaires de la BA

- Endocardite infectieuse (30%)
- Sténose valvulaire (53% des RA calcifiés de l ’adulte ont une BA)
- Insuffisance valvulaire

Evolution des lésions valvulaires chez l ’enfant

- 70 patients avec gdient <25, suivi de 5 ans
  - 28% RA modéré (gdient max entre 25 et 50)
  - 9% RA sévère (gdient max > 75)
- 44 patients gdient max entre 25 et 50
- 36% RA sévère à 3.7 ans.

Eragli Ped Cardiol 2006

Evolution valvulaire

- Seuls 15% des patients ont une valve de fonctionnement normal après 50 ans
- 2/3 des patients développent une sténose aortique
- 50% des RA sont des bicuspidies
- IA : mécanismes multiples
  - dilatation de la racine aortique et de l ’anneau
  - prolapsus d’un feuillet
  - processus dégéneratif
  - rétraction
  - endocardite

Age à l'opération en fonction de la morphologie de la valve

Aortic Valve Structure in 584 Men and 348 Women Aged 26 to 91 Years With Operatively Excised Stenotic Aortic Valves Unassociated With Mitral Valve Disease and Excised From 1993 to 2004

Aortic Valve Structure	Cases, n (%)							
		21–30	31–40	41–50	51–60	61–70	71–80	81–90
Men								
Unicuspid	34 (6)	3	4	11	8	4	4	0
Bicuspid	309 (53)	1	4	20	54	111	94	24
Tricuspid	234 (40)	0	0	0	14	50	119	51
Uncertain	7 (1)	0	0	0	0	3	2	2

Complications de la BA : le RA

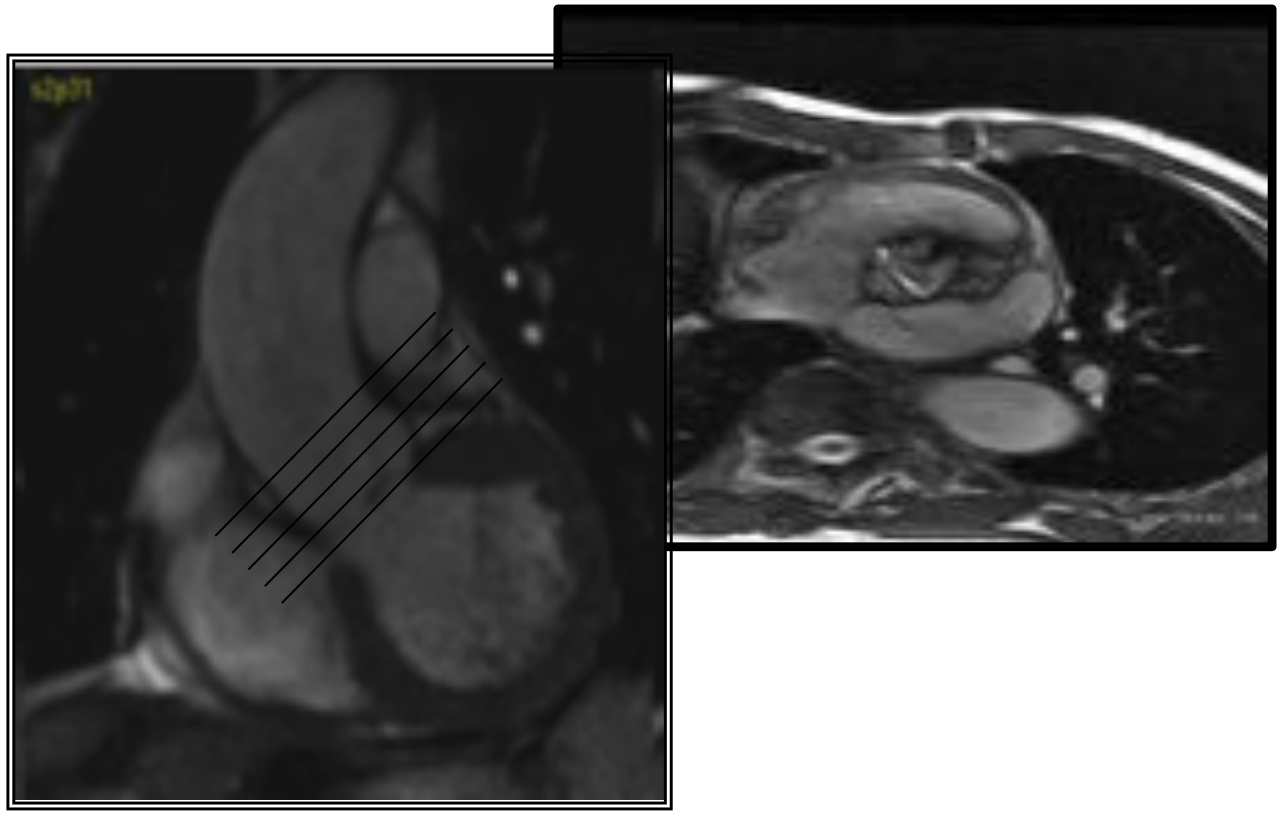

Lésions associées

- Angio RM avec injection de gadolinium

- 50% des sujets jeunes avec une valve aortique bicuspide fonctionnant normalement ont une dilatation aortique

Angio-IRM : Dilatation de l'Aorte Ascendante

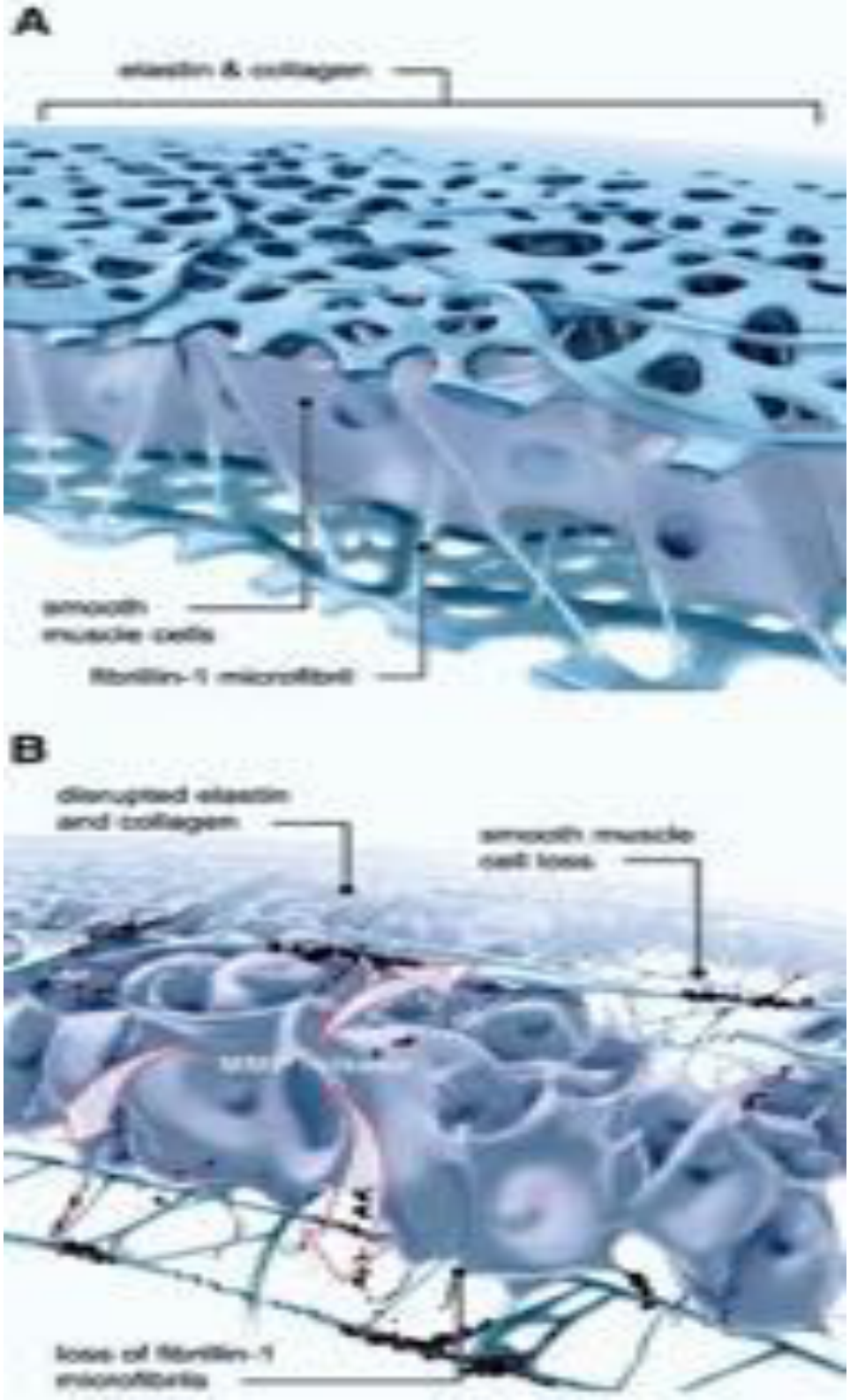

Dilatation de l ’aorte

Normal tricuspid valves

fibrillin-1 microfibrils tether smooth muscle cells to adjacent elastin and

collagen matrix components

Fedak et al. *Circulation* 2002

Bicuspid aortic valves

deficient microfibrillar elements result in smooth muscle cell detachment, MMP release, matrix disruption, cell death, and a loss of structural support and elasticity.

Etude échographique
jeunes hommes service militaire (n=66)

% aorte normale

7,5% 19,6% 15% 43%

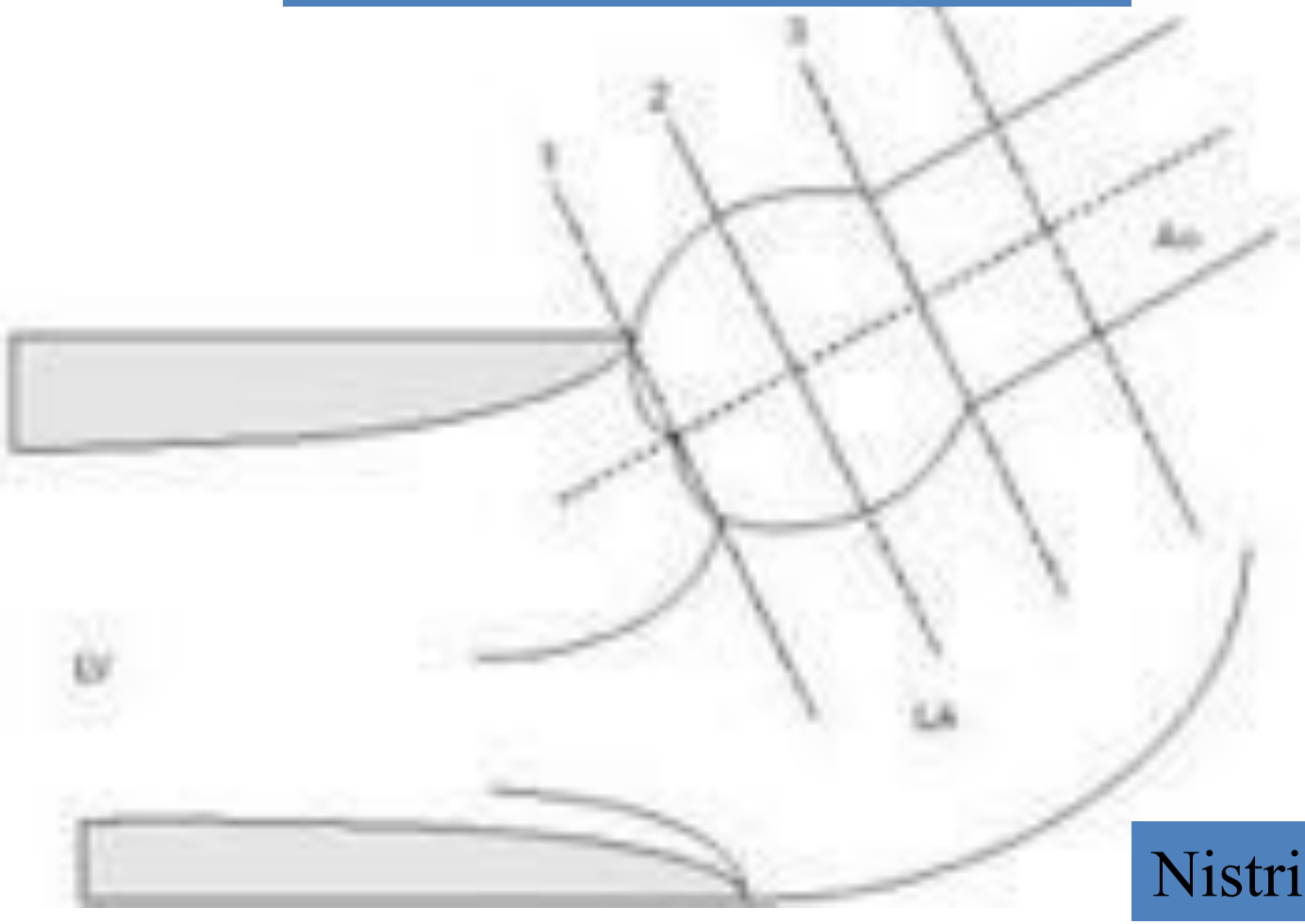

Nistri, heart 1999

Intervention sur la valve ne prévient pas la dilatation aortique



Figure 1. Annual dilation rate in each group. SV=sinuses of Valsalva; STJ=sinotubular junction; Prox. Ao=proximal aorta 1 cm above the sinotubular junction. The dilation rate of the BAV-OP patients tended to be faster than that of TAV-OP patients.

Yasuda Circ 2003

Dilatation de l ’aorte associée à la valvulopathie

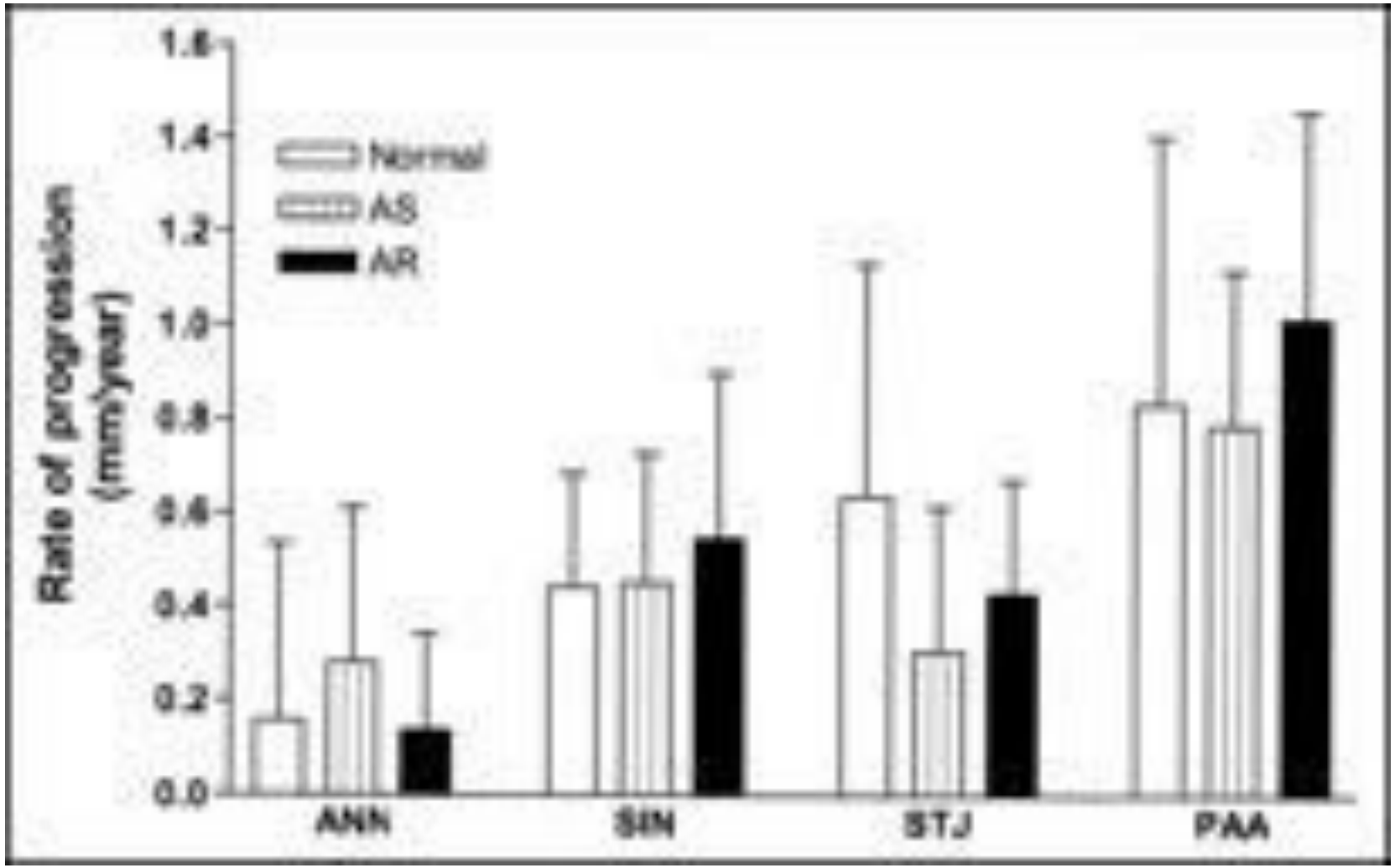

Rythme moyen de progression de la dilatation 0.9 mm/an

SURVEILLANCE

- Echo annuelle
- IRM ou Scanner chez l ’adulte car parfois aorte asymétrique et mesures écho non fiables
- beta bloquants raisonnables….
- Aspirine? Traiter le cholesterol
- SURVEILLER++++
- prévention de l ’Osler
- grossesse à risque de dissection (seuil???)

Quand opérer?

- Valve aortique fuyante ou sténosante
- aorte ascendante quand diamètre > 50mm ou progression rapide
- remplacer l'aorte ascendante en cas de chirurgie valvulaire si diamètre > 45mm
- ou si grossesse envisagée

Conclusion: Bicuspidie

- Malformation cardiaque congénitale la plus fréquente (prévalence de 1%) dépistage familial
- Héréditaire, sexe ratio : 4 hommes /1 femme
- Maladie de toute la racine aortique
- Complications valvulaires et aortiques
- **Le scanner et l'IRM constituent une imagerie de choix (vs ETT/ETO**) chez l 'adulte

Sténose sous aortique

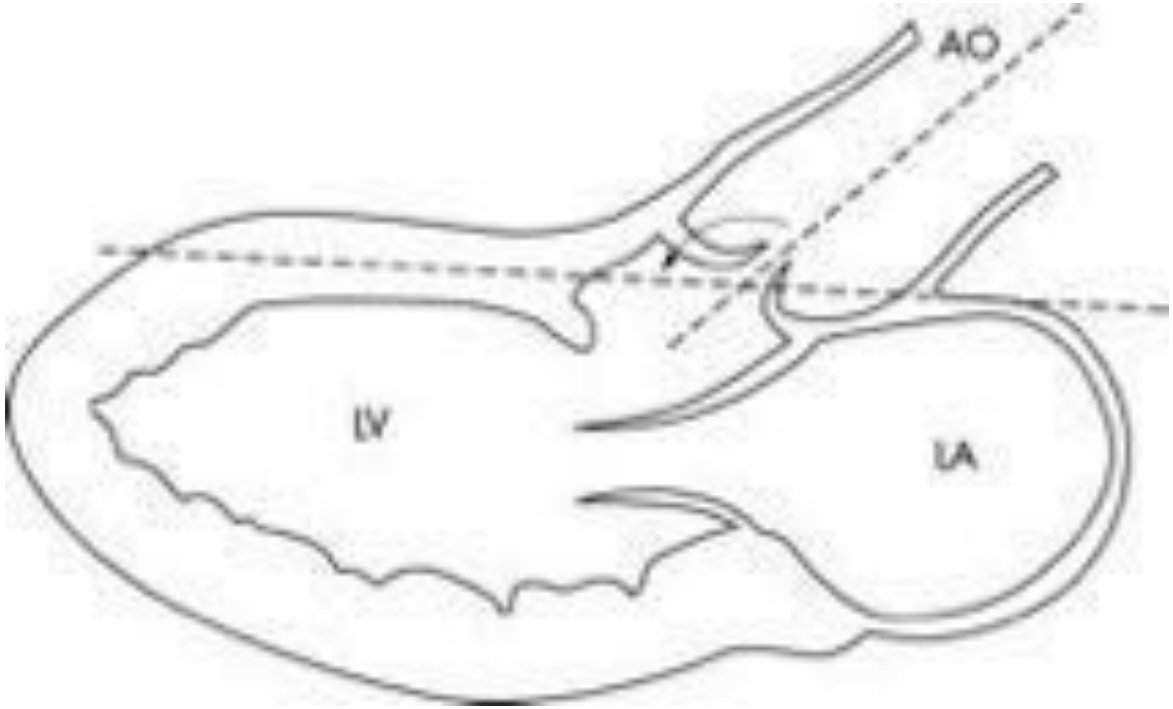

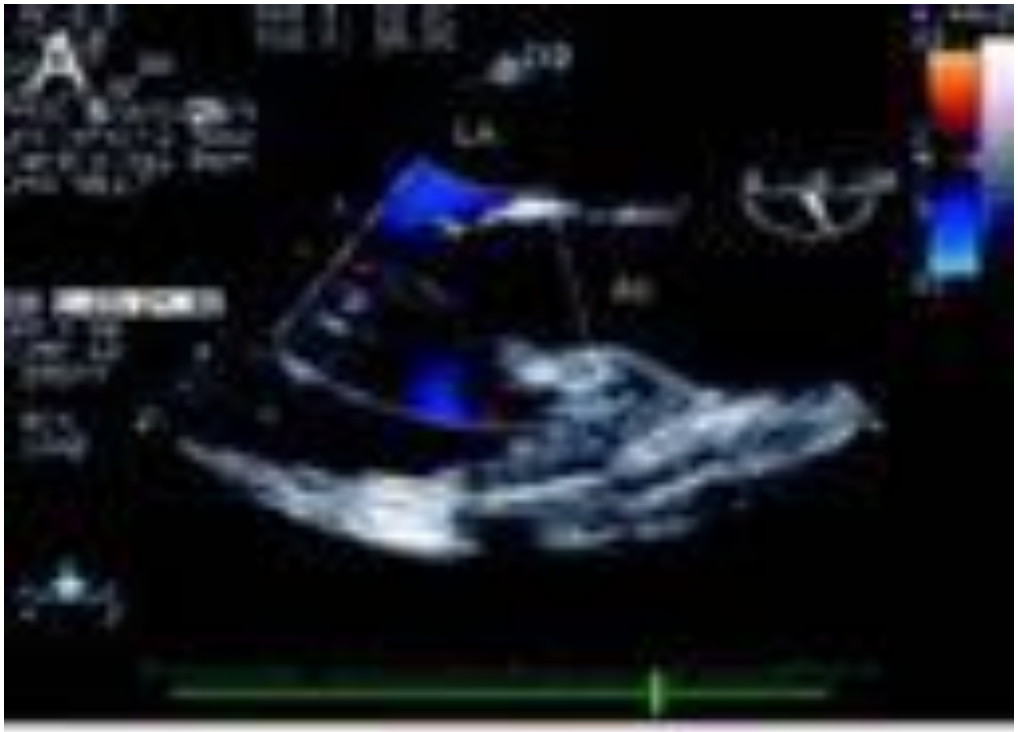
A
LA
AO

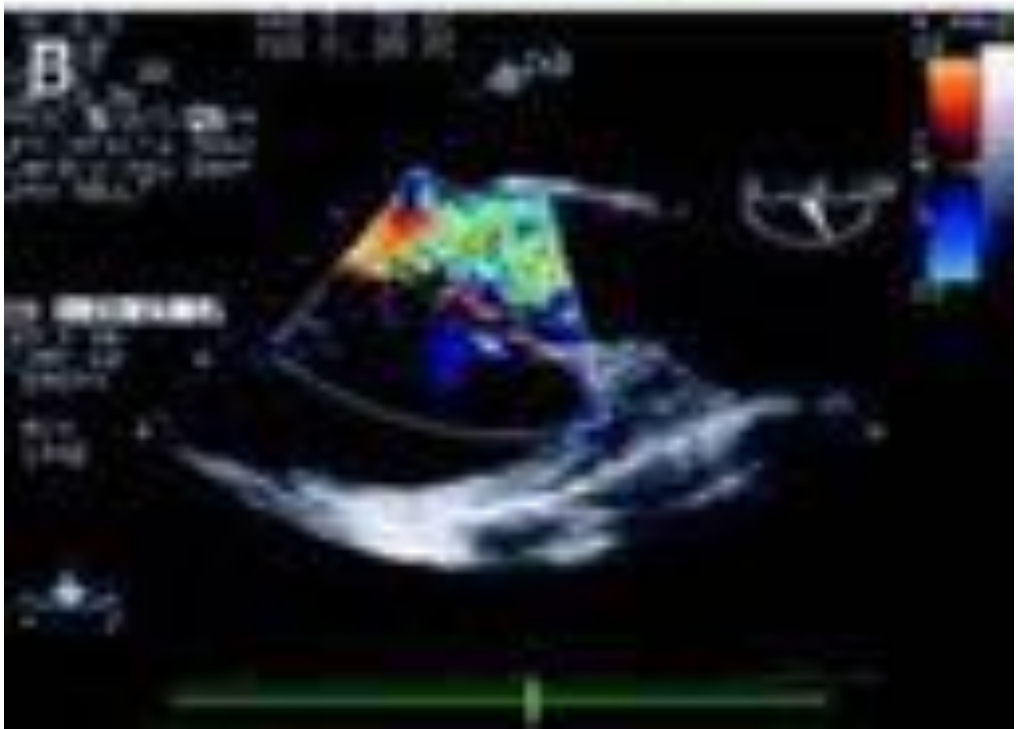
B

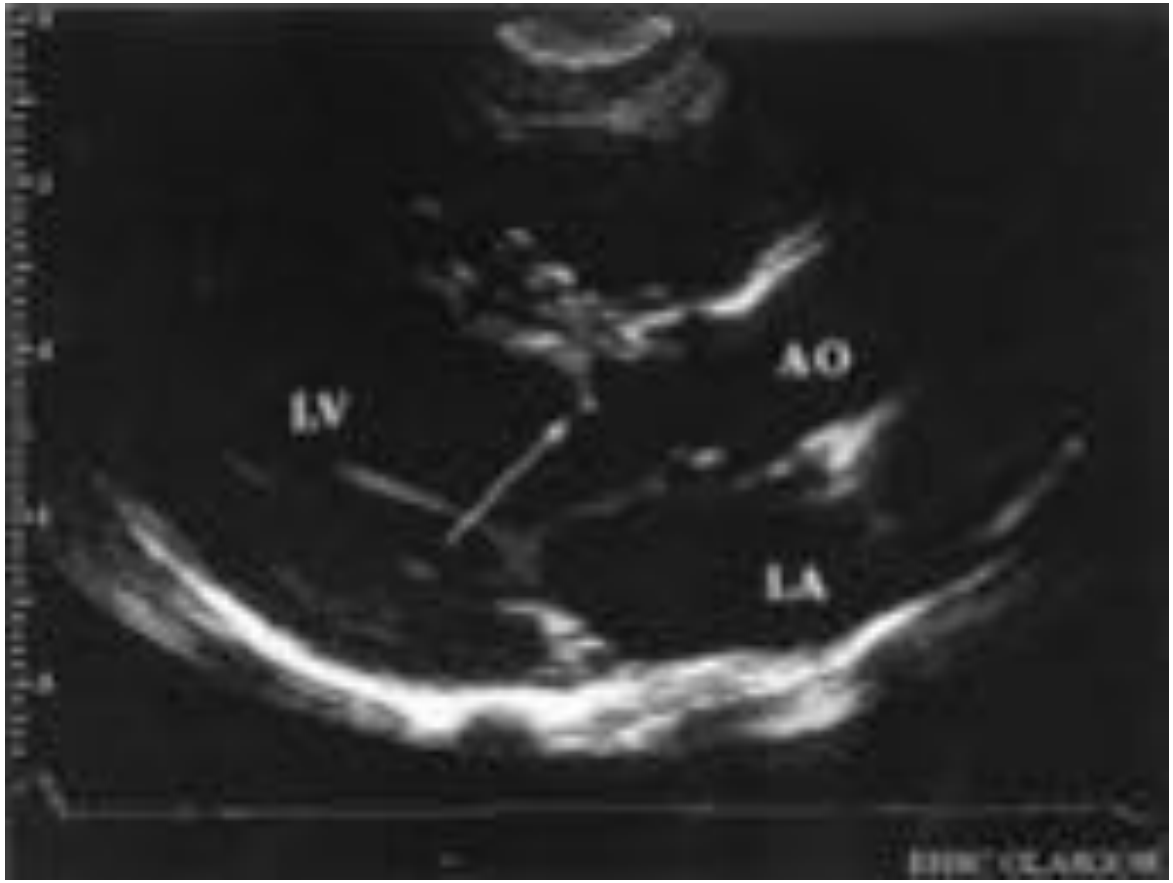
AO
LV
LA

LA
ADV
LVOT

Conclusion :

- pathologies intriquées
- Suivi multidisciplinaire
    - particularités de l’adulte
- Peu d évolution de la membrane sous aortique
- Evoquer les interventions sans valve mecanique chez la jeune femme
- (ross , homogreffe)
- Toujours penser a l’aorte en meme temps que la valve, et regarder la mitrale