

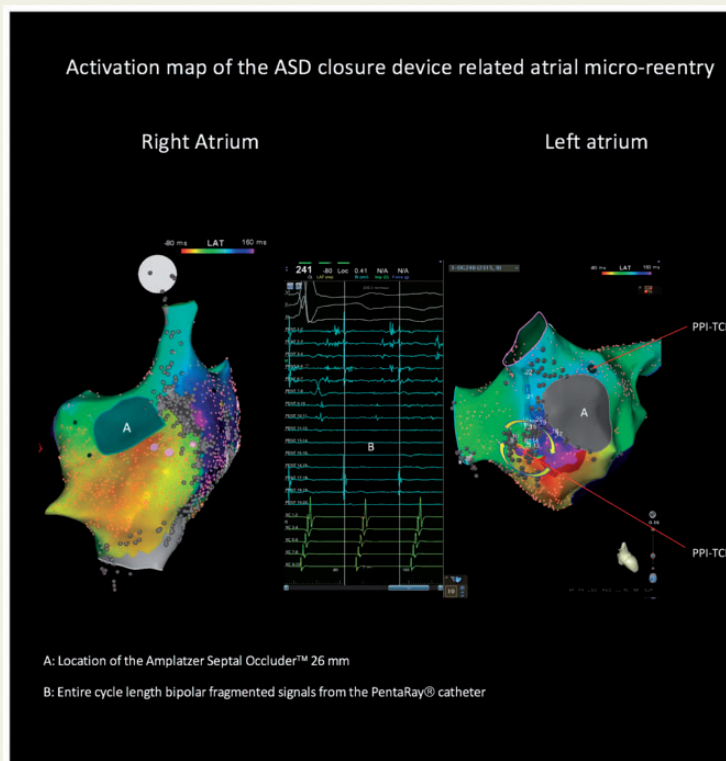
## Left atrial flutter after implantation of atrial septal occluder

Alexandre Zhao\*, Clément Karsenty, and Magalie Ladouceur

Adult Congenital Heart Disease Unit, Department of Cardiology, European Hospital Georges Pompidou, 75015 Paris, France

\* Corresponding author. Tel: +33 621428039. E-mail address: alexandre.zhao@gmail.com

A 30-year-old man was referred for catheter ablation of a symptomatic atrial flutter 1 year after a secundum atrial septal defect (ASD) closure with an Amplatzer septal Occluder (ASO 26 mm, St Jude Medical). After trans-septal puncture through the native atrial septum, electroanatomical biatrial mapping showed an early activation coming from the right interatrial septum below the ASO. Local electrogram on the left atrium showed a fractionated low voltage continuous signal, which was consistent with a re-entry between the ASO and the right pulmonary veins. Focal radiofrequency ablation terminated the tachycardia. We described, here, a left atrial re-entry related to percutaneous ASD device closure.



**Conflict of interest:** none declared.

Published on behalf of the European Society of Cardiology. All rights reserved. © The Author(s) 2018. For permissions, please email: journals.permissions@oup.com.