




Contents lists available at ScienceDirect

International Journal of Cardiology

journal homepage: www.elsevier.com/locate/ijcard

4D flow MRI versus conventional 2D for measuring pulmonary flow after Tetralogy of Fallot repair

M.A. Isorni^a, D. Martins^{b,c}, N. Ben Moussa^a, S. Monnot^a, N. Boddart^d, D. Bonnet^b, S. Hascoet^a, F. Raimondi^{b,d,*}

^a Unité de radiologie diagnostique et thérapeutique, Hôpital Marie Lannelongue, 133, avenue de la résistance, 92350, Le Plessis Robinson, France

^b Unité médicochirurgicale de cardiologie congénitale et pédiatrique, centre de référence des maladies cardiaques congénitales complexes — M3C, Hôpital universitaire Necker—Enfants-Malades, 149, rue de Sèvres, 75743, Paris, Cedex 15, France

^c Pediatric Cardiology Unit, Hospital de Santa Cruz, Lisboa, Portugal

^d Pediatric Radiology Unit, Hôpital universitaire Necker—Enfants-Malades, 149, rue de Sèvres, 75743, Paris, Cedex 15, France

ARTICLE INFO

Article history:

Received 3 April 2019

Received in revised form

20 September 2019

Accepted 18 October 2019

Available online xxx

ABSTRACT

Background: After tetralogy of Fallot (TOF) repair, pulmonary regurgitation and right ventricular function must be monitored. Conventional (2D) cardiac magnetic resonance (CMR) is currently the clinical reference method for measuring pulmonary regurgitation. However, 4DFlow CMR has been reported to provide a more comprehensive flow analysis than 2D CMR. We aimed to compare 4DFlow CMR to 2D CMR for assessing pulmonary regurgitation and flow, as well as aortic flow, in children and adults after surgical repair of TOF.

Methods: Retrospective analysis of patients with repaired TOF admitted for cardiac MRI with 4DFlow acquisition from 2016 to 2018. Linear regression was used to assess correlations and Bland-Altman analyses were performed.

Results: The 60 included patients had a mean age of 18.2 ± 10.4 years (range, 2–54 years).

Significant correlations between the two techniques were found for pulmonary regurgitant fraction ($R [2] = 0.6642$, $p < 0.0001$), net pulmonary flow ($R [2] = 0.6782$, $p < 0.0001$), forward pulmonary flow ($R [2] = 0.6185$, $p < 0.0001$), backward pulmonary flow ($R [2] = 0.8192$, $p < 0.0001$), and aortic valve flow ($R [2] = 0.6494$, $p < 0.0001$). The Bland-Altman analysis showed no significant bias, narrow limits of agreement, and few scattered points. The correlation between pulmonary and aortic flow was better with 4DFlow CMR than with 2D CMR ($R [2] = 0.8564$, $p < 0.0001$ versus $R [2] = 0.4393$, $p < 0.0001$, respectively). Interobserver reliability was good.

Conclusion: These results establish the feasibility and reliability of 4DFlow CMR for assessing pulmonary flow in a large paediatric and adult population with repaired TOF. 4DFlow CMR may be more reliable than 2D MRI for pulmonary flow assessment after TOF repair.

© 2019 Elsevier B.V. All rights reserved.

Tetralogy of Fallot (TOF), the most prevalent cyanotic congenital heart disease, is usually corrected surgically in the first year of life [1].

Whatever the type of right ventricle (RV) outflow tract corrective surgery (transannular patch, homograft or a valve preserving technique), it mostly consists in infundibulotomy with or without

an incision across the pulmonary valve annulus leading to pulmonary valve insufficiency and to right ventricular enlargement [2–5]. The haemodynamic burden generated by these alterations increases over time, potentially resulting in arrhythmias, exercise intolerance, heart failure, and sudden cardiac death [3,4,6,7]. TOF repair must therefore be followed by close monitoring of the pulmonary regurgitation fraction (PRF) and of RV function, for which the current reference standard technique is 2D cardiac magnetic resonance (2D CMR), due to its better performance compared to echocardiography, cardiac computed tomography, and cardiac catheterization [8,9]. However, 2D CMR has a number of drawbacks (slow processing, need for breath-holding, relationship between

* Corresponding author. Unité médicochirurgicale de cardiologie congénitale et pédiatrique, centre de référence des maladies cardiaques congénitales complexes — M3C, Hôpital universitaire Necker—Enfants-Malades, 149, rue de Sèvres, 75743, Paris, Cedex 15, France.

E-mail address: francesca.raimondi@gmail.com (F. Raimondi).

voxel size and signal-to-noise ratio) that limit its use in clinical practice.

An innovative cardiac flow measurement method based on time-resolved 3D phase-contrast magnetic resonance imaging (MRI) and known as 4DFlow CMR was introduced recently. This modality enables both qualitative and quantitative flow analyses based on data from a single, free-breathing sequence [10].

The purpose of this study was to evaluate the performance of 4DFlow CMR for assessing aortic and pulmonary artery flows in patients of any age who had a history of surgical repair of TOF. The reference standard used for the assessment was 2D CMR. Our hypothesis was that 4DFlow CMR would provide accurate flow values, similar to those obtained using 2D CMR, but with better consistency and reproducibility.

1. Methods

1.1. Study population

We retrospectively included all patients with a history of surgical repair of TOF (with pulmonary stenosis or atresia) who were admitted to two tertiary hospitals for cardiac MRI with 4DFlow acquisition from January 2016 to September 2018. We also included 10 randomly selected healthy controls scheduled for CMR with gadolinium injection. The study was approved by local ethic committee, which waived the need for informed consent in compliance with French law on retrospective studies of anonymized data.

1.2. 2D CMR acquisition

CMR acquisitions were performed with the 1.5-T Discovery MR450 machine (GE Healthcare, Milwaukee, WI, USA). The images were acquired during a breath hold if possible, or during free-breathing in patients younger than 6 years, with retrospective electrocardiographic (ECG)-gating (TR/TE, 5.0/2.9 ms; flip angle, 16°; field of view, 320; 30 phases per cardiac cycle). The velocity encoding value was adapted individually to yield images without aliasing artefacts (200–400 cm/s). Effective flow was measured at the level of the pulmonary valve, perpendicularly to the axis of the pulmonary artery; and at the level of the aortic valve, perpendicularly to the long axis of the ascending aorta (Fig. 1). The images were read by two experienced paediatric cardiologists (13 and 5 years' experience with congenital heart disease imaging, respectively), who were blinded to the 4DFlow CMR results. Quantification of 2D flows and flow pattern calculations (forward flow, backward flow, PRF, and net flow) were performed using dedicated software (Qmass 7.2, Medis, Leiden, The Netherlands). Flow values were corrected using the stationary flow fit method.

1.3. 4DFlow CMR acquisition

All 4DFlow CMR flow data were acquired using a gadolinium-based contrast agent (Gadovist 1 mmol/mL, Bayer, Mijdrecht, The Netherlands) and the same 1.5-T Discovery MR450 machine as for 2D CMR. The images were acquired during free-breathing, using retrospective ECG gating to produce a three-dimensional volume covering the entire heart. The parameters were as follows: TR/TE, 2.7/2.2 ms; flip angle, 10°; acquisition voxel, 2.1 × 2.1 × 2.4 mm; reconstructed voxel size, 1.4 × 1.4 × 1.2 mm; with 30 phases reconstructed during one average cardiac cycle. The velocity encoding value was individually adapted to yield images without aliasing artefacts (200–400 cm/s). Raw data were processed using dedicated software (Arterys Inc., San Francisco, CA, USA). 4DFlow quantifications were assessed using cloud-based image reconstruction after data correction.

The pulmonary and aortic valve and pulmonary arteries were identified within the volumetric data set on the double-oblique cross-sectional views. Two blinded observers read the images independently. Each reader measured flows by interrogating the jet avoiding regions of velocity-aliasing and following the motion of the valve during the cardiac cycle adjusting valve plane by “valve tracking” function.

1.4. Statistical analysis

Continuous data were described as mean ± SD and categorical data as number (%). Forward flow, backward flow, and PRF values obtained using 4DFlow CMR and 2D CMR (Fig. 1 and Data in brief Video 1 and 2) were compared. Distribution normality was checked using the Shapiro-Wilk test. The Chi2 test was used for comparing categorical variables and Student's *t*-test for comparing continuous variables. Potential confounders were included in the statistical model. The relative risks (RRs) were computed with their 95% confidence intervals (95% CIs). Values of *p* below 0.05 were taken to indicate significant differences. Interobserver reliability was assessed based on Pearson's correlation coefficients, Bland-Altman plots [11], and the intraclass correlation coefficients (ICC) [12]. The statistical analyses were performed using JMP 9.1 software (SAS Institute Inc., Cary, NC, USA). Aortic flow values were used as the reference for both 2D CMR and 4DFlow CMR.

2. Results

Table 1 reports the main baseline characteristics of the 60 included patients, the half of them were paediatric patients (age range, 2–18 years). Complete acquisitions were obtained in all patients.

Mean PRF was 27.0% ± 17.1%. Mean pulmonary artery (PA) flows were as follows: forward flow, 6.6 ± 2.3 L/min; backward flow, 2.0 ± 1.7 L/min; and net flow, 4.6 ± 1.6 L/min. Mean cardiac output was 4.6 ± 1.2 L/min.

Table 2 reports Pearson's correlation coefficients between 4DFlow CMR and 2D CMR values of PRF, forward PA flow, backward PA flow, and net PA flow. Linear regression demonstrated significant correlations for PRF (Fig. 2), forward PA flow (Data in brief Fig. 1), and backward PA flow (Data in brief Fig. 2). The Bland-Altman analysis showed no significant bias, narrow limits of agreement, and few scattered points. For net PA flow, the correlation was good and the Bland-Altman analysis showed a mean difference close to zero with limited dispersion (Data in brief Figure 3). Net aortic flow values obtained by 2D CMR and 4DFlow CMR also showed a good correlation (Data in brief Figure 4).

Linear regression analysis demonstrated a good correlation between net PA flow and net aortic flow measured by 4DFlow CMR (Data in brief Figure 5). The Bland-Altman analysis revealed a negative bias apparently related to high flow values; for lower flows, the values produced by the two methods showed greater similarity. With 2D CMR, net PA flow and net aortic flow also showed a good correlation with each other (Data in Brief Figure 6 and 7), but weaker if compared to 4DFlow CMR. Moreover, aortic flow compared to the sum of left and right pulmonary artery showed a much better correlation with 4D Flow CMR than with 2D CMR (Data in brief Figure 8 and 9).

The correlations and levels of agreement between the two flow measurement methods were similar in the 10 controls to those in the 60 patients. Interobserver variability and intraobserver variability were similar, with no difference in the 95% CIs estimated for the various correlation coefficients.

The ICC values were good with both methods: 4DFlow CMR, 0.91–0.99 and 2D CMR, 0.88–0.89 for interobserver variability

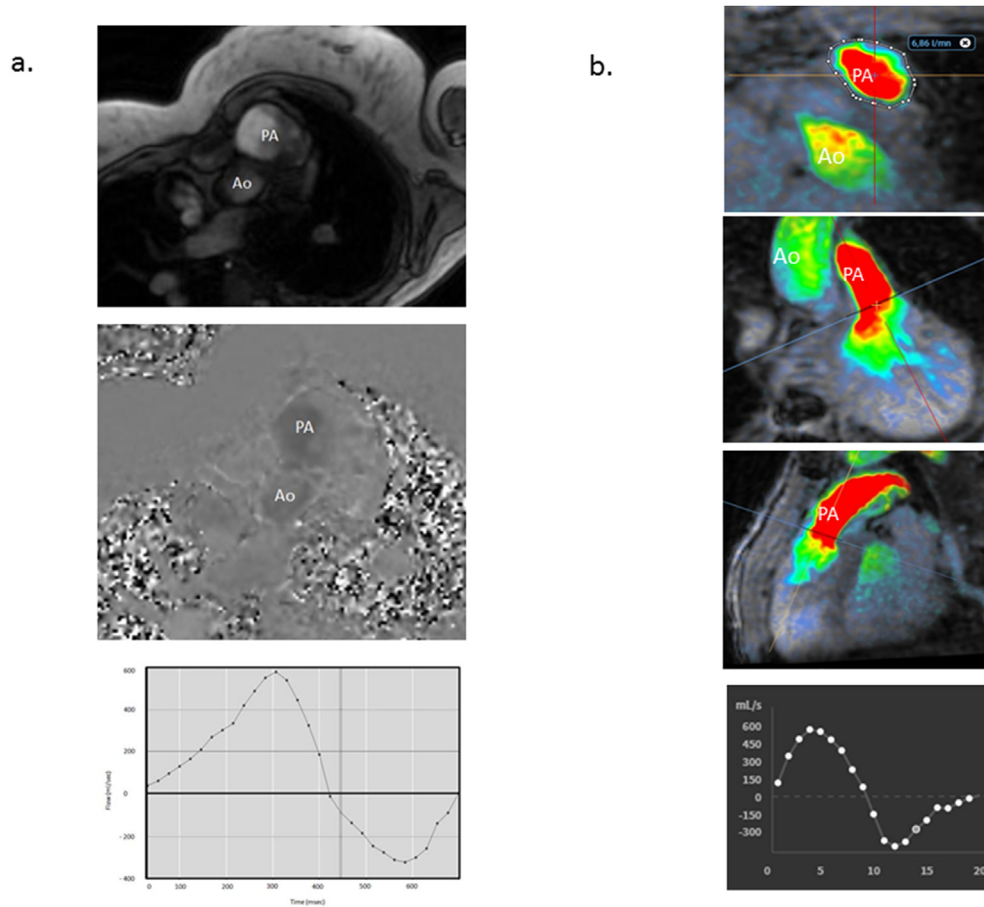


Fig. 1. Pulmonary artery flow assessment using 2D CMR and 4DFlow CMR. 22-year-old patient with repaired Tetralogy of Fallot. a, b: magnitude and phase-contrast images in a plane axial to the main pulmonary artery. c: assessment of forward and backward flows based on the anterograde and retrograde volumes showing a pulmonary regurgitation fraction of 32%. PA, pulmonary artery; Ao, aortic valve. d, e: images reconstructed from 4DFlow CMR flow data at the level of pulmonary artery: major regurgitation during diastole. f, g: regurgitation fraction of 33%. PA, pulmonary artery; Ao, aortic valve; RA, right atrium; RV, right ventricle.

Table 1

Baseline characteristics.

Patients (n)	60
Age, years, mean ± SD (range)	18.2 ± 10.4 (2–54)
Height, cm, mean ± SD	155.6 ± 16.8
Weight, kg, mean ± SD	54.1 ± 19.2
Heart rate, bpm, mean ± SD	69.3 ± 6.5
Clinical presentation, n (%)	
. healthy	10 (17)
. repaired tetralogy of Fallot	50 (83)

Table 2

Comparison of flows by 2D and 4D cardiac magnetic resonance assessed based on Pearson's correlation coefficient (R).

	Mean ± SD	R [95%CI]	p value
Pulmonary regurgitation fraction (%)	27 ± 17	R = 0.81 [0.69–0.88]	<0.001
PA net flow (L/min)	4.6 ± 1.6	R = 0.82 [0.72–0.89]	<0.001
PA forward flow (L/min)	6.6 ± 2.3	R = 0.90 [0.84–0.94]	<0.001
PA backward flow (L/min)	2.0 ± 1.7	R = 0.92 [0.87–0.95]	<0.001
Ao net flow	4.4 ± 1.5	R = 0.80 [0.68–0.89]	<0.001
4D CMR: net flows, L/min, PA versus Ao	4.6 ± 1.2	R = 0.89 [0.81–0.93]	<0.001
2D CMR: net flows, L/min, PA versus Ao	4.4 ± 1.1	R = 0.71 [0.52–0.83]	<0.001

95%CI, 95% confidence interval; PA, pulmonary artery; Ao, aortic valve; CMR, cardiac magnetic resonance.

(Data in brief Table 1); 4DFlow CMR, 0.95–0.97 and 2D CMR, 0.88–0.90 for intraobserver variability (Data in brief Table 2).

3. Discussion

To the best of our knowledge, this is an innovative study comparing 2D CMR and 4DFlow CMR for assessing pulmonary flow in children and adults with pulmonary regurgitation after surgery for TOF with pulmonary stenosis or atresia. [13,14], Our patients covered a broad spectrum of clinical situations after TOF repair in terms of age and haemodynamic characteristics.

The results found in the patient population with repaired TOF

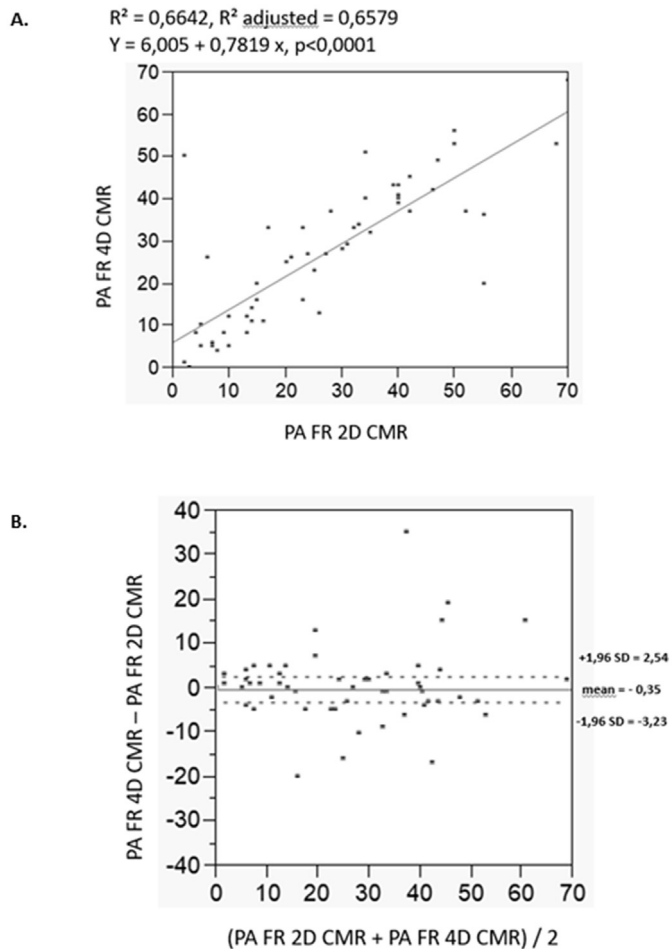


Fig. 2. a: Linear regression of pulmonary regurgitation fraction (PFR) estimated using 4DFlow CMR versus 2D CMR. b: Bland-Altman graphs comparing PFR by 4DFlow CMR versus 2D CMR.

were replicated in controls with normal haemodynamic, supporting the good performance of 4DFlow CMR comparatively to 2D CMR. The comparison of 2D CMR and 4DFlow CMR by linear regression showed close correlations. The Bland-Altman analyses indicated good agreement between these two quantitative measurement methods. However, there was a negative bias that seemed related to high flow values, as data on low flows were more closely similar between the two flow measurement methods. These results may be ascribable to the paucity of data on high flow rates. However, the bias and range of agreement indicated smaller differences between the two methods than would be clinically relevant.

We found close correlations and good agreement between systemic and pulmonary artery flow assessed using 4DFlow CMR. The linear regression analysis revealed excellent correlations in variables acquired by 4DFlow CMR. Similarly, the Bland-Altman analysis showed no significant bias, as well as good agreement with limited dispersion and narrow confidence intervals. In contrast, the comparison of aortic and pulmonary artery flow estimated by 2D CMR showed weaker correlations and a lower degree of agreement, with less satisfactory interobserver variability. Moreover, the correlation between aortic and the sum of left and right pulmonary artery flows measured by 2D CMR was poor while the same analysis with 4DFlow CMR was absolutely consistent. These results suggest that 4D Flow MRI may offer better

reliability and consistency than 2D MRI.

Phase-contrast 2D CMR is widely used in clinical practice to assess pulmonary regurgitation, and is currently considered the reference standard. However this examination is particularly complex, requiring a great medical and paramedical expertise, is time-consuming both for acquisition and interpretation and thus generates a certain discomfort for the patients and particularly for the children with frequent recourse to a more or less deep sedation. This point is particularly relevant in patients with repaired congenital heart defects, whose cardiac anatomy is modified by the surgical procedures in a way that varies from patient to patient, creating challenges in identifying the acquisition planes [8,15,16]. Moreover, 2D CMR doesn't allow the tracking of the valve plane, while 4D flow CMR does. Several authors demonstrated that valve tracking method improve reliability and accuracy of flow measurement [17–19].

We used in our analysis the tracking method integrated in Arterys software that has the advantage of not requiring conventional 2D bright blood cine imaging in two and four chamber views as other different tracking methods do.

It would be interesting in future works to test different methods of tracking to find the most accurate one.

Our results suggest that 4DFlow CMR gives more consistent results in comparison to the 2D CMR reference technique, with greater reproducibility, while requiring less acquisition time, with a single free breathing sequence. Therefore, 4DFlow sequence should be considered a useful tool in current practice, reliable and efficient to study patients with Tetralogy of Fallot, particularly in children.

Recent data from Geva et al. (5) suggest that in patients after repair of Tetralogy of Fallot timing for pulmonary valve replacement should rely on comprehensive evaluation of cardiac anatomy and physiology. It seems to us that 4D imaging is the ideal tool, allowing an overall assessment of cardiac anatomy and function coupled to complete flow analysis with unlimited post processing, and –based on our study– a better reproducibility.

4. Limitations of the study

Main limitation of this study is that the gold-standard reference is based on the same physical basis. It is therefore impossible to determine which of the two methods is the most accurate. However, it should be considered that 4DFlow CMR allows a global evaluation of the flows in a complete volume with unlimited retrospective analysis capacity, whereas the 2D CMR is limited to prospective focused analysis. As a result, it seems to us that this technique offers the best internal consistency data.

Finally, even though the machines are identical at both sites and acquisition protocols are common, we cannot exclude minor variations in the settings for each exam depending on the patient and the magnetic environment for 2D CMR and 4DFlow CMR.

5. Conclusion

The results of this study illustrate the feasibility and reliability of 4DFlow CMR for assessing pulmonary artery flow in a large population of paediatric and adult patients. 4DFlow CMR was more reliable than 2D CMR. Our findings support the use of 4DFlow CMR as the method of choice for flow assessment in patients with congenital heart defects.

References

- [1] J. Therrien, G. Webb, Clinical update on adults with congenital heart disease, *The Lancet* 362 (2003) 1305–1313.
- [2] J. Villafañe, J.A. Feinstein, K.J. Jenkins, R.N. Vincent, E.P. Walsh, A.M. Dubin,

- T. Geva, J.A. Towbin, M.S. Cohen, C. Fraser, J. Dearani, D. Rosenthal, B. Kaufman, T.P. Graham, Hot topics in tetralogy of Fallot, *J. Am. Coll. Cardiol.* 62 (2013) 2155–2166.
- [3] H. Kim, S.C. Sung, S.-H. Kim, Y.H. Chang, H.D. Lee, J.A. Park, Y.S. Lee, Early and late outcomes of total repair of tetralogy of Fallot: risk factors for late right ventricular dilatation, *Interact. Cardiovasc. Thorac. Surg.* 17 (2013) 956–962.
- [4] P.G. Sfyridis, G.V. Kirvassilis, J.K. Papagiannis, D.P. Avramidis, C.G. Ieromonachos, P.N. Zavaropoulos, G.E. Sarris, Preservation of right ventricular structure and function following transatrial-transpulmonary repair of tetralogy of Fallot, *Eur. J. Cardiothorac. Surg.* 43 (2013) 336–342.
- [5] T. Geva, B. Mulder, K. Gauvreau, S.V. Babu-Narayan, R.M. Wald, K. Hickey, A.J. Powell, M.A. Gatzoulis, A.M. Valente, Preoperative predictors of death and sustained ventricular tachycardia after pulmonary valve replacement in patients with repaired tetralogy of Fallot enrolled in the INDICATOR cohort, *Circulation* 138 (2018) 2106–2115.
- [6] N. Dłużniewska, P. Podolec, M. Skubera, M. Smaś-Suska, J. Pająk, M. Urbańczyk-Zawadzka, W. Płazak, M. Olszowska, L. Tomkiewicz-Pająk, Long-term follow-up in adults after tetralogy of Fallot repair, *Cardiovasc. Ultrasound* 16 (2018) 28.
- [7] A.A. Amirghofran, J. Badr, M. Jannati, Investigation of associated factors with post-operative outcomes in patients undergoing Tetralogy of Fallot correction, *BMC Surg.* 18 (2018) 17.
- [8] T. Geva, Repaired tetralogy of Fallot: the roles of cardiovascular magnetic resonance in evaluating pathophysiology and for pulmonary valve replacement decision support, *J. Cardiovasc. Magn. Reson.* 13 (2011) 9.
- [9] K. Hanneman, A.M. Crean, B.J. Wintersperger, P. Thavendiranathan, E.T. Nguyen, C. Kayedpour, R.M. Wald, The relationship between cardiovascular magnetic resonance imaging measurement of extracellular volume fraction and clinical outcomes in adults with repaired tetralogy of Fallot, *European Heart Journal - Cardiovascular Imaging* 19 (2018) 777–784.
- [10] P. Dyverfeldt, M. Bissell, A.J. Barker, A.F. Bolger, C.-J. Carlhäll, T. Ebbers, C.J. Francios, A. Frydrychowicz, J. Geiger, D. Giese, M.D. Hope, P.J. Kilner, S. Kozerke, S. Myerson, S. Neubauer, O. Wieben, M. Markl, 4D flow cardiovascular magnetic resonance consensus statement, *J. Cardiovasc. Magn. Reson.* 17 (2015) 72.
- [11] J.M. Bland, D.G. Altman, Measuring agreement in method comparison studies, *Stat. Methods Med. Res.* 8 (1999) 135–160.
- [12] P.E. Shrout, J.L. Fleiss, Intraclass correlations: uses in assessing rater reliability, *Psychol. Bull.* 86 (1979) 420–428.
- [13] R.G. Chelu, K.W. Wanambiro, A. Hsiao, L.E. Swart, T. Voogd, A.T. van den Hoven, M. van Kranenburg, A. Coenen, S. Boccalini, P.A. Wielopolski, M.W. Vogel, G.P. Krestin, S.S. Vasanawala, R.P.J. Budde, J.W. Roos-Hesslink, K. Nieman, Cloud-processed 4DFlow CMR flow imaging for pulmonary flow quantification, *Eur. J. Radiol.* 85 (2016) 1849–1856.
- [14] P. Sjöberg, J. Töger, E. Hedström, P.M. Arvidsson, E. Heiberg, H. Arheden, R. Gustafsson, S. Nozohoor, M. Carlsson, Altered biventricular hemodynamic forces in patients with repaired Tetralogy of Fallot and right ventricular volume overload due to pulmonary regurgitation, *Am. J. Physiol. Heart Circ. Physiol.* 315 (6) (2018) H1691–H1702.
- [15] P.A. Davlouros, P.J. Kilner, T.S. Hornung, W. Li, J.M. Francis, J.C.C. Moon, G.C. Smith, T. Tat, D.J. Pennell, M.A. Gatzoulis, Right ventricular function in adults with repaired tetralogy of Fallot assessed with cardiovascular magnetic resonance imaging: detrimental role of right ventricular outflow aneurysms or akinesia and adverse right-to-left ventricular interaction, *J. Am. Coll. Cardiol.* 40 (2002) 2044–2052.
- [16] S.A. Rebergen, J.G. Chin, J. Ottenkamp, E.E. van der Wall, A. de Roos, Pulmonary regurgitation in the late postoperative follow-up of tetralogy of Fallot. Volumetric quantitation by nuclear magnetic resonance velocity mapping, *Circulation* 88 (1993) 2257–2266.
- [17] A. Hsiao, U. Tariq, M.T. Alley, M. Lustig, S.S. Vasanawala, Inlet and outlet valve flow and regurgitant volume may be directly and reliably quantified with accelerated, volumetric phase-contrast MRI, *J. Magn. Reson. Imaging* (2014) 376–385.
- [18] S.D. Roes, S. Hammer, R.J. van der Geest, N.A. Marsan, J.J. Bax, H.J. Lamb, J.H. Reiber, A. de Roos, J.J. Westenberg, Flow assessment through four heart valves simultaneously using 3-dimensional 3-directional velocity-encoded magnetic resonance imaging with retrospective valvtracking in healthy volunteers and patients with valvular regurgitation, *Investig. Radiol.* 44 (10) (2009 Oct) 669–675.
- [19] V.P. Kamphuis, A.A.W. Roest, N. Ajmone Marsan, P.J. van den Boogaard, L.J.M. Kroft, J.P. Aben, J.J. Bax, A. de Roos, H.J. Lamb, Westenberg JJM, Automated cardiac valve tracking for flow quantification with four-dimensional flow MRI, *Radiology* 290 (1) (2019 Jan) 70–78.